



ROBOTIC RADICAL GASTRECTOMY - OWN EXPERIENCE AND REVIEW OF LITERATURE



Rafał Roszkowski, Maksymilian Baryła, Andrzej Piotr Kwiatkowski

Wojskowy Instytut Medyczny – Państwowy Instytut Badawczy, Klinika Chirurgii Ogólnej, Onkologicznej, Metabolicznej i Torakochirurgii, Polska

Rafał Roszkowski – 0000-0002-2633-1153

Maksymilian Baryła – 0000-0003-1668-7188

Andrzej Piotr Kwiatkowski – 0000-0001-6288-7725

Abstract:

Introduction

Gastric cancer is the fifth most common cancer worldwide. Surgery or endoscopic treatment is essential in all disease stages. The most common procedure is total gastrectomy with D2 lymphadenectomy. Removal of stomach and lymph nodes can be performed using minimally invasive techniques. These include laparoscopic gastrectomy, present in gastric cancer surgery since 1994 and robotic gastrectomy, which appeared for the first time in 2003. Last-mentioned method is the youngest and the most technically advanced form of surgical treatment of gastric cancer. First laparoscopic robot-assisted total gastrectomy in Poland was reported by Marek Zawadzki. In this paper we present technique of totally robotic total gastrectomy.

Aim

Presentation of our experience in robotic radical gastrectomy. Description of first in Poland totally robotic gastrectomy. Review of literature assessing novel minimally invasive technique in gastric cancer treatment - robotic gastrectomy.

Material and methods

Presentation of our own experience in robotic surgery. Review of literature.

Results

Robotic gastrectomy as an alternative to the laparoscopic technique is associated with earlier return of bowel motility after surgery and earlier introduction of a liquid diet. In terms of perioperative and postoperative complications, morbidity, and mortality, as well as a need to convert to open surgery, the laparoscopic and robotic techniques do not differ from each other. In our Department for the first time in Poland totally robotic radical gastrectomy using da Vinci Xi ® Surgical System (Intuitive Surgical) was performed. No postoperative complications were observed.

Conclusions

Totally robotic radical gastrectomy is a safe alternative to classic and laparoscopic surgery which can have additional benefits both for the surgeon (less exhaustion, ergonomics, lack of hand tremor on instruments) as for the patient (earlier tolerance of oral diet, earlier hospital discharge). Further study is needed to assess relevance of potential benefits and cost-effectiveness of this novel technique.

Keywords: gastric cancer, robotic gastrectomy, da Vinci, lymphadenectomy D2.

DOI 10.53301/lw/159868

Received: 2022-11-30

Accepted: 2023-01-26

Corresponding author:

Rafał Roszkowski

Wojskowy Instytut Medyczny- Państwowy Instytut Badawczy, Klinika Chirurgii Ogólnej, Onkologicznej, Metabolicznej i Torakochirurgii, Warszawa

e-mail: rafro89@gmail.com

Introduction

Gastric cancer is the fifth most common cancer worldwide, responsible for 7.7% of cancer deaths [1]. Surgical or endoscopic treatment is essential in all disease stages [1]. The most common procedure is total gastrectomy with D2 lymphadenectomy. In stage IA-III B (T1N0M0 - T3N2M0) there is a possibility of subtotal gastrectomy depending on the tumor location and in stage 0 cancers (TisN0M0) neoplastic tumor can be removed by endoscopic mucosectomy [2]. Endoscopic resection is also possible in early T1 stages, however not all patients will benefit from this treatment. Survival outcomes in T1a gastric cancers vary significantly depending on race. For example the rate of lymph node metastasis in T1a gastric cancers in the United States is higher than the rates reported in Asia [3] thus local endoscopic resection is inferior to gastrectomy for early clinical stage T1a and T1b gastric adenocarcinoma in the United States [4].

Apart from the first method used historically- open gastrectomy, removal of the stomach and lymph nodes can be performed with the use of minimally invasive techniques. These include laparoscopic gastrectomy, present in gastric cancer surgery since 1994 [5] and robotic gastrectomy, which appeared for the first time in 2003 [6-7]. Last-mentioned method is the youngest and the most technically advanced form of surgical treatment of gastric cancer. First laparoscopic robot-assisted total gastrectomy in Poland was reported by Marek Zawadzki [8]. The laparoscopic part of the procedure involved opening the lesser sac, mobilization of the greater curvature and transection of the duodenum. A robot was used for D2 lymphadenectomy and creation of anastomosis. In this paper we present technique of totally robotic total gastrectomy.

Aim

To present and assess novel minimally invasive technique in gastric cancer treatment- robotic gastrectomy.

Material and methods

We present our experience in robotic surgery which led to first in Poland totally robotic gastrectomy with lymphadenectomy D2 as well as the review of literature.

Results

Own experience

55-year-old man was admitted on September 29, 2021 for the surgical treatment of gastric cancer. In gastroscopic examination, crater-like ulcers with raised, sharply delimited walls of about 4 cm were observed in gastric cardia area. Walls and bottom of the lesion were described as hard, brittle, and flaky. The histopathological examination of the samples showed the presence of high-grade adenocarcinoma G3. After the diagnosis was made, the patient was under the care of the Department of Oncology, where further treatment was planned. Before elective gastrectomy, the patient received 4 cycles of FLOT chemotherapy. CT scan of the chest, abdominal cavity and pelvis with contrast showed thickening (with

a maximum vertical dimension of 16 mm) of the walls of the abdominal esophagus and stomach around the cardia, fundus and partially the lesser curvature with smoothing the stomach folds. Three lymph nodes sized < 5 mm were visible in gastric cardia area. There was no infiltration of the surrounding organs and vessels, no visible metastases, and no destructive changes in the bones. In CT scan after four cycles of neoadjuvant chemotherapy, a marked reduction in the thickening of the gastric cardia wall was observed. The lymph nodes did not enlarge.

The patient was previously diagnosed with arterial hypertension and had not undergone any surgical procedures before.

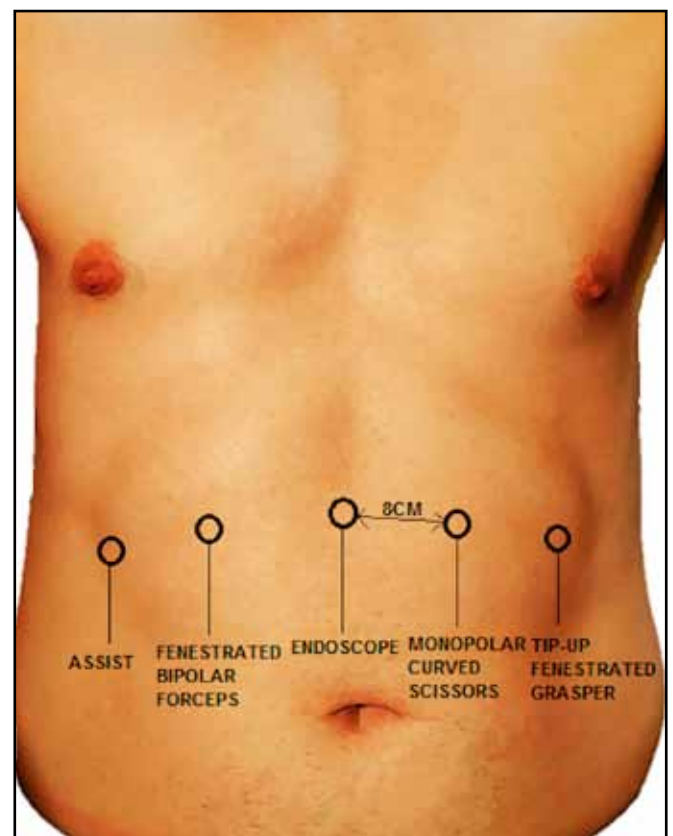
Laboratory tests on admission showed no abnormalities in electrolyte balance, renal and coagulation system parameters. The peripheral blood count was normal.

Based on the histological type of the lesion, location, clinical stage, and the lack of metastases, the patient had been qualified to robotic gastrectomy with the use of the da Vinci Xi® Surgical System (Intuitive Surgical).

Procedure description

Robotic gastrectomy was performed on September 30, 2021. After disinfection and sterile draping of the operating field, under general anesthesia, a Veress needle was inserted at the Palmer's point. Pneumothorax was set to 12 mm Hg. The first 8 mm robotic trocar and endoscope were introduced. Under visual control another three 8 mm robotic trocars and an assistant trocar were introduced (Fig. 1).

Figure 1. Trocars placement.



Then the appropriate position of the operating table was set. The intestines were arranged, revealing the operating field. Robotic trocars were attached to the robot's „patient cart”. The trocars were placed to the correct depth under visual control, and the tension was released. Robotic tools were installed: Tip-up Forceps, Fenestrated Bipolar Forceps and Monopolar Scissors. The stomach and the greater omentum were dissected, the blood vessels supplying the organ were clipped with polymer clips and cut. The duodenum was divided distal to the pylorus with the use of the iDrive Ultra® (Covidien) stapler (45 mm gold cartridge) (Fig. 2). D2 lymphadenectomy was performed (Fig. 3-4) and the resected tissues were sent for histopathological examination. The jejunum was cut with the stapler (60 mm white cartridge) about 15 cm from the Treitz ligament. The mesentery was divided, and the Roux en Y loop was created. The distal part of the intestine was moved through a pre-made opening under the mesocolon and the intestine was mechanically anastomosed with the esophagus (45 mm gold cartridge) with the use of using the self-pulling technique (SPLT). The esophagus was cut with a stapler (60 mm purple cartridge) just above the gastric cardia (Fig. 5). The remaining opening in the anastomosis was sutured (Fig. 6). Functional end to end anastomosis (FETEA) was created (Fig. 7). The proximal part of the jejunum was mechanically anastomosed side-to-side with the small intestine about 60 cm from the esophagojejunal anastomosis (Fig. 8). The remaining opening in the anastomosis was closed by double layer running suture (Fig. 9). The leak test of the esophagojejunal anastomosis was performed with the use of methylene blue solution. No leak was detected. The afferent loop was fixed to the opening in transverse colon mesentery and the remaining opening in the small bowel mesentery was closed. Pfannenstiel incision in the lower abdomen was made, edges of the wound were secured with an Alexis Wound Protector® (Applied Medical). The stomach, the greater omentum and the other excised tissues were removed from abdominal cavity (than sent for histopathological examination). Two 16F drains were left in the peritoneal cavity.

Figure 2. Duodenum was divided distal to the pylorus.

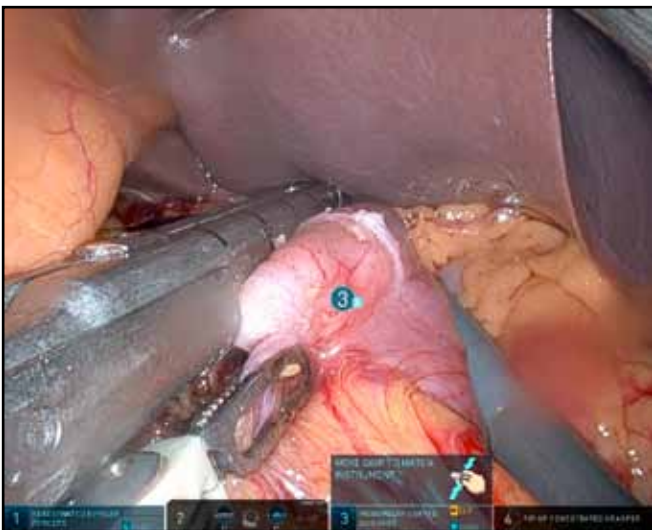


Figure 3. D2 lymphadenectomy was performed.

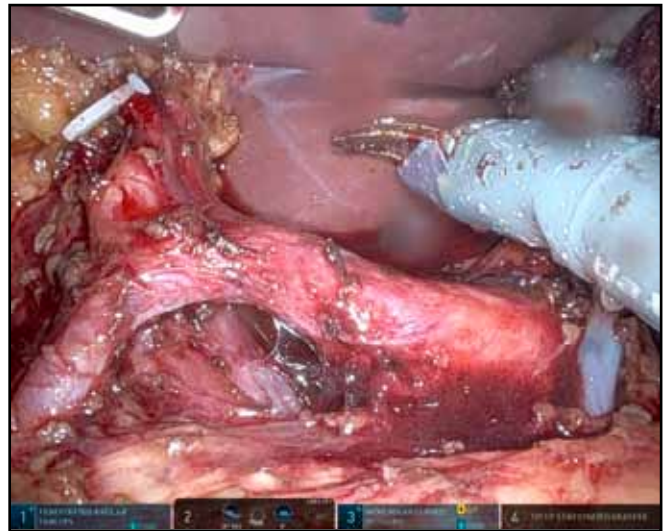


Figure 4. D2 lymphadenectomy was performed.

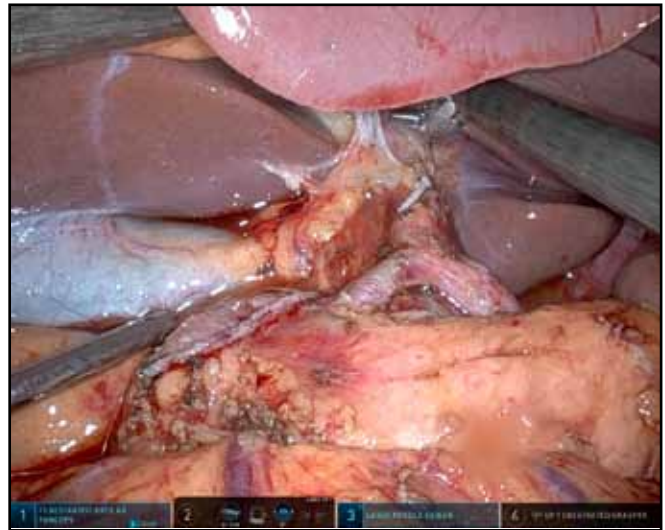


Figure 5. Esophagus was cut with a stapler just above the gastric cardia.

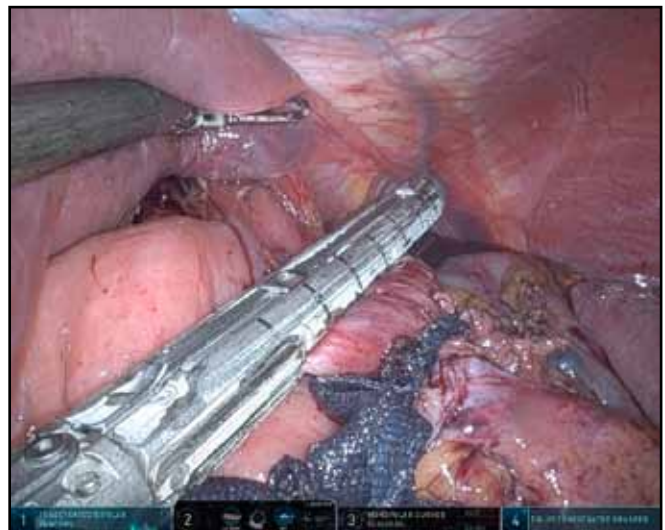


Figure 6. Opening in the anastomosis was sutured.

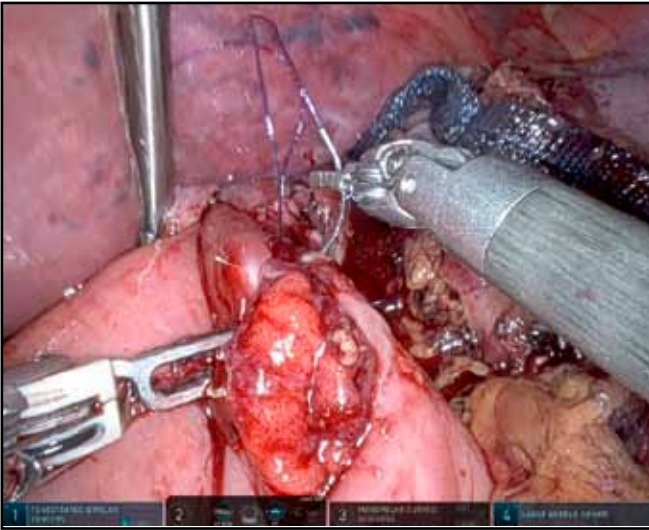


Figure 7. Functional end to end anastomosis was created.

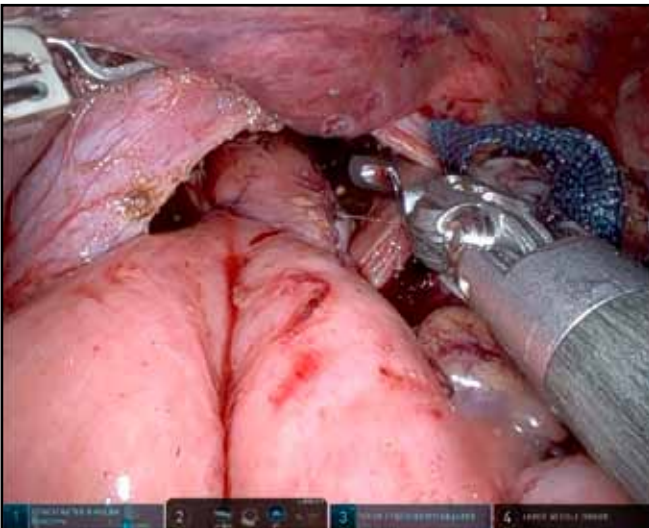


Figure 8. Proximal part of the jejunum was mechanically anastomosed side-to-side with the small intestine.

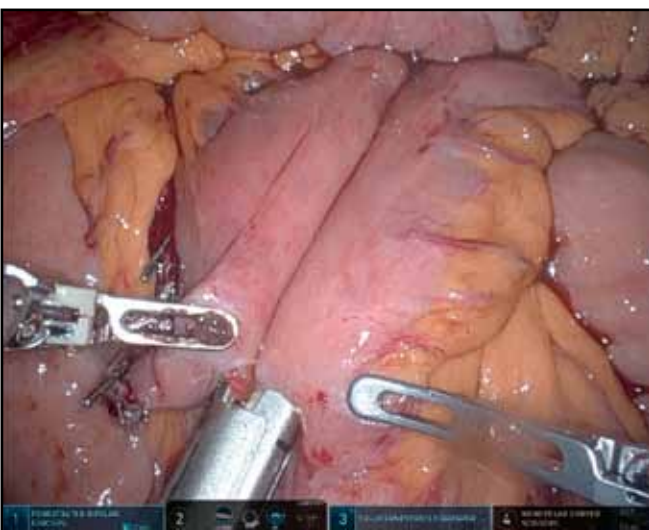
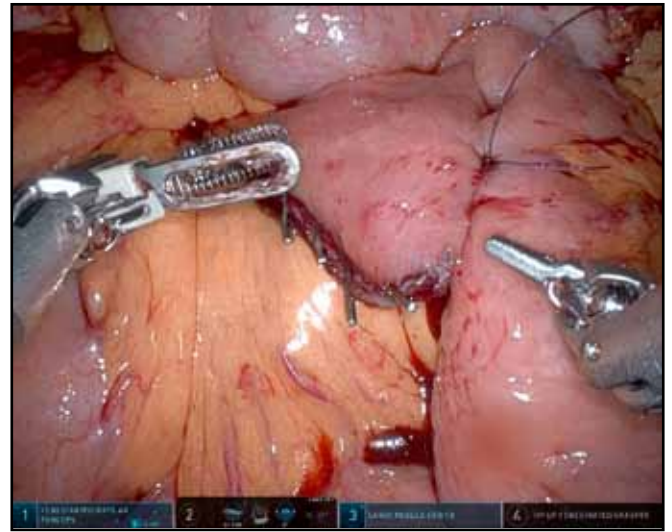


Figure 9. Opening in the anastomosis was closed by double layer running suture.



Postoperative care

In the early postoperative period daily fluid balance, basic vital signs and the volume and appearance of fluid collected by drains were monitored. The patient did not have a fever. There were no signs of surgical site infection.

In laboratory tests, a slight decrease in hemoglobin concentration to 10 g/dl was observed (preoperative hemoglobin concentration was 11.9 g/dl), clinically with no evidence of active bleeding. The serum levels of α -amylase, urea and creatinine remained within the normal range. The concentration of C-reactive protein was 2.3; 5.6 and 3.6 mg/dl on the first, second and fourth postoperative days, respectively. On the first postoperative day, an increased concentration of creatine kinase was noted (it normalized in the days following the procedure).

In the histopathological examination of the excised tissues (stomach with the greater omentum, mediastinal site, common hepatic artery site, hepatoduodenal ligament site, celiac trunk sit, upper edge of the pancreas site, lesser curvature and the greater curvature site), no cancer cells were found. The biopsy obtained from ulcer found in stomach in the preoperative gastroscopy was again examined. The primary diagnosis was confirmed (high grade cancer, G3). Taking into account that the patient had received four cycles of chemotherapy prior to gastrectomy, a complete response to this treatment was observed (according to UICC CR). In the current study, according to the TNM classification, the tumor was assessed as ypT0CR ypN0 (0/29) R0 tumor.

The patient was discharged home in good general condition on the sixth day after surgery.

Discussion

Nowadays there is no meta-analysis which compares the amount of minimally invasive procedures conducted in Asia and in Europe. Most of clinical trials are based on an experience from the Asian centers. This phenomenon is

caused by the higher incidence of gastric cancer in Asian countries such as Japan or South Korea [9-11]. In Europe gastric cancer is less frequent however there are also some analyses focused on minimally invasive procedures in gastric cancer treatment. In 2015 the registry called IMIGASTRIC was established [12-13]. The purpose of this clinical trial is to create a "multi-institutional database comprising of information regarding surgical, clinical and oncological features of patients undergoing surgery for gastric cancer with robotic, laparoscopic or open approaches and subsequent follow-up at participating centers" [13]. The data about different types of gastric surgery was collected from North America, Europe, and Asia, but the results are not available yet [14].

In a meta-analysis Jianglei Ma et al. [15] compared laparoscopic and robotic gastrectomy. It showed that perioperative blood loss is reduced in robotic gastrectomy group (WMD: 28.66; 95% CI 18.59 - 38.73, $p < 0.001$). Meta-analysis by Xinsheng Zhang et al. showed that robotic gastrectomy with D2 lymphadenectomy required a longer operating time (WMD = 29.78, 95% confidence interval (CI): 15.97-43.59) but it had less operative blood loss (WMD = -31.93, 95% CI: -44.03 to -19.83), shorter time to first flatus (WMD = -0.13, 95% CI: -0.22 to -0.04), shorter time to liquid diet (WMD = -0.20, 95% CI: -0.28 to 0.12), and fewer severe complications (RR = 0.62, 95% CI: 0.43-0.90) and overall complications (RR = 0.75, 95% CI: 0.62-0.91) compared with laparoscopic gastrectomy with D2 lymphadenectomy [16].

A statistically significant difference was also obtained in the studies by Binghong Xiong et al. [18], Leonardo Solaini et al. [19] and Li-Dong Hu et al. [20].

Similar conclusions were obtained on the basis of a retrospective analysis by Weisong Shen et al. [17], but only in the subgroup of patients whose tumor did not infiltrate the serosa (176.6 ± 217.2 ml for robotic gastrectomy vs. 212.5 ± 198.8 ml for laparoscopic gastrectomy, $P = 0.001$). In the subgroup of patients with serosa involvement, no statistically significant difference was found in the amount of blood lost perioperatively.

In a retrospective analysis by Taeil Son et al. [21], in which both techniques were compared (total gastrectomy with lymphadenectomy D2), no statistically significant difference was noticed in the amount of blood lost perioperatively (163 vs. 210 ml; $P = 0.360$). Data collected by Hong-Bin Liu et al. [22] and J. M. Park et al. [23] also showed no differences in this parameter for both techniques. In the case of gastrectomy performed without D2 lymphadenectomy, perioperative blood loss also did not differ for both robotic and laparoscopic gastrectomy [23].

It should be emphasized that the BMI in patients with gastric cancer does not affect the amount of estimated blood loss, which was shown in a prospective study by J.M. Park et al. [23] and Juhan Lee et al. [24].

Another analyzed parameter is the number of lymph nodes removed during the operation. It is an important issue for further oncological treatment and the overall patients survival. Most of the studies conducted so far have reported a greater number of obtained lymph nodes for

robotic rather than laparoscopic gastrectomy (Weisong Shen et al. for the subgroup of patients without serosa involvement [17]: 33 ± 8.5 vs. 31.3 ± 9.5 , $P = 0.047$; Taeil Son et al. [21] 47.2 vs. 42.8 , $P = 0.210$; Hong-Bin Liu et al. [22] 40.9 ± 13.1 vs. 35.4 ± 15.8 ; $P = 0.004$; Li-Dong Hu et al. [20]). On the other hand, in the studies of Jianglei Ma et al. [9], Binghong Xiong et al. [18], Taeil Son et al. [21], Liang Zong et al. [25] there were no significant differences in the number of obtained lymph nodes. Weisong Shen et al. also did not show such a difference for the subgroup of patients with serosa involvement [17].

Taeil Son et al. [21] showed that although the total number of lymph nodes did not differ for both techniques, more lymph nodes were obtained from the area of splenic artery, spleen hilum and abdominal aorta. Retrospective analysis of Myung-Han Hyun et al. [26] showed that in obese patients, the number of lymph nodes obtained during robotic gastrectomy was lower (23.4 ± 7.0) than during laparoscopic gastrectomy (32.2 ± 12.5 , $P = 0.006$). The same conclusions were obtained in the prospective study of Juhan Lee et al. [24] for the group of patients undergoing subtotal gastrectomy with D2 lymphadenectomy.

Duration of gastrectomy performed with the robotic technique is longer compared to the laparoscopic technique (according to Weisong Shen et al. [17] 257.1 ± 74.5 min vs. 226.2 ± 61.3 min respectively, $p < 0.001$; according to Kuo-Hung Huang et al. [27] 357.9 ± 107.8 min vs. 319.8 ± 113.7 min respectively, $p = 0.040$; according to Leonardo Solaini et al [19] 327 min (297-358) vs. 248 min (222-275) respectively, $p = 0.001$) [9, 18, 20, 23, 24]. In studies by Hong-Bin Liu et al. [22] and Myung Han Hyun et al. [26] there was no difference in the time of surgery for both techniques. However, it should be emphasized that these studies are based on data from procedures performed by a single surgeon. In a prospective study by Juhan Lee et al. [24] the effect of obesity on the difference in surgery time was not confirmed for both minimally invasive techniques.

A factor that may influence further oncological treatment is the time from surgery to hospital discharge, because the shorter this time, the sooner the patient can receive adjuvant chemotherapy. In the studies of Hong-Bin Liu et al. [22] and Weisong Shen et al. [17] this time for robotic gastrectomy was shorter compared to laparoscopic gastrectomy (Hong-Bin Liu et al.: 11 days (9-13) vs. 12 days (10-14) respectively, $p < 0.0001$; Weisong Shen et al.: 9.4 ± 7.5 days vs. 10.6 ± 10.9 days respectively, $p = 0.41$). Binghong Xiong et al. did not observe significant differences in length of hospital stay after surgery (WMD: 0.42, 95% CI: -1.87 to 0.79; $P = 0.42$) [18].

Robotic gastrectomy as an alternative to the laparoscopic technique is also associated with earlier return of bowel motility after surgery and an introduction of a liquid diet [20,22].

In terms of perioperative and postoperative complications, morbidity, and mortality, as well as a need to convert to open surgery, the laparoscopic and robotic techniques do not differ from each other [9, 17, 18, 20, 21, 22, 24, 27, 28].

In the meta-analysis by Jianglei Ma et al. [9] there were no statistically significant differences in overall survival (HR = 0.95, 95% CI 0.76 ~ 1.18, P = 0.640), relapse-free survival (HR = 0.91, 95% CI 0.69 ~ 1.21, P = 0.530) and the recurrences (OR = 0.90, 95% CI 0.67 ~ 1.21, P = 0.500). Similar results for overall survival and disease-free survival are described in the retrospective analysis of Taeil Son et al. [21].

Based on the literature, robotic gastrectomy also has no advantage over laparoscopic gastrectomy in terms of the R0 resection rate [17] and in terms of resection margins free of neoplasm [9, 20, 28].

Robotic gastrectomy is one of the most advanced surgical methods in the treatment of gastric cancer. Learning curves have also been studied over the past decade. Kuo-Hung Huang et al. [27, 29] in both the 2012 and 2014 analyzes, observed the plateau phase of the learning curve in terms of operating time and the time needed to apply the necessary equipment after 25 robotic gastrectomy procedures. In the study of Hong-Bin Liu et al. [22] after adopting the cut-off point of 25 treatments as a learning curve, no significant differences were observed in duration of surgery and installation of equipment after another 75 treatments. Kuo-Hung Huang et al. [27] determined the learning curve for 41 performed procedures for laparoscopic gastrectomy in patients with gastric cancer. Operation time and perioperative blood loss decreased with experience. These conclusions, however, require verification in subsequent studies, as the current data are insufficient to estimate the learning curve for robotic gastrectomy and conclude that this curve is shorter compared to the learning curve for laparoscopic gastrectomy. There have also been reports that experience in laparoscopic gastrectomy positively influences a learning curve in robotic gastrectomy [30-31].

As presented above, there is a lack of clear consensus regarding both minimally invasive techniques. There is no such discrepancy when comparing robotic gastrectomy to open surgery. Data from retrospective studies and meta-analyzes are consistent. Robotic gastrectomy is associated with a longer duration of the procedure [25, 32, 33], perioperative blood loss is lower than in classic surgery [25, 32, 33], and a stay in hospital ward is also shorter in a group of patients undergoing robotic surgery. In a meta-analysis by M. H. Hyun et al. [33] this period was shorter by an average of 2.18 days (P < 0.001). There are no significant differences in postoperative complications such as bleeding, wound infection, anastomotic leakage [32-33]. There are also no differences in number of removed lymph nodes [25, 32-33]. Length of resection margin also does not differ between the two techniques [33].

Comparing postoperative mortality and morbidity for classic and robotic surgery, based on the meta-analyzes quoted above [25, 32], it can be concluded that both methods are equally safe.

Conclusions

To sum up, robotic gastrectomy is a safe alternative to classic and laparoscopic surgery. In addition to the high-resolution three-dimensional image of the operating

field, da Vinci Xi® Surgical System provides amenities such as surgeon's hand vibration filter and wrist instruments that provide seven degrees of freedom, which gives greater scope and precision of maneuvers in a narrow operating field.

Robotic surgery compared to open surgery, apart from a better cosmetic effect, has an advantage in terms of the time from surgery to discharge from hospital. Comparing it with laparoscopic surgery, it is difficult to demonstrate additional benefits for the patient. According to the experience of the authors of the publication, work ergonomics during robotic procedures (compared to open and laparoscopic techniques) has improved for both the operator and the assistant, and thus long surgical procedures have become less physically demanding. In addition, da Vinci Xi® Surgical System connects wirelessly with TruSystem 7000dV Operating Table so that a patient can be dynamically positioned while the surgeon operates (Integrated Table Motion).

A certain limitation, when it comes to the availability of this modern technology, may be the cost of purchasing the robotic system itself and the cost of its further operation.

Further research and postoperative supervision are needed to verify whether robotic gastrectomy will improve the patients' quality of life of and extend disease-free survival.

Disclosures section

Authors have nothing to disclose.

References

1. Mocan L. Surgical Management of Gastric Cancer: A Systematic Review. *J Clin Med*, 2021; 10 (12): 2557. DOI: 10.3390/jcm10122557
2. Songun I, Putter H, Meershoek-Klein Kranenbarg E, et al. Surgical treatment of gastric cancer: 15-year follow-up results of the randomised nationwide Dutch D1D2 trial. *Lancet Oncol*, 2010; 11: 439-49. DOI: 10.1016/S1470-2045(10)70070-X
3. Audrey H Choi , Rebecca A Nelson , Shaila J Merchant, et al. Rates of lymph node metastasis and survival in T1a gastric adenocarcinoma in Western populations. *Gastrointest Endosc*, 2016 Jun; 83 (6): 1184-1192.e1. DOI: 10.1016/j.gie.2015.10.039
4. Sivesh K Kamarajah, Sheraz R Markar, Alexander W Phillips, et al. Local Endoscopic Resection is Inferior to Gastrectomy for Early Clinical Stage T1a and T1b Gastric Adenocarcinoma: A Propensity-Matched Study. *Ann Surg Oncol*, 2021 Jun; 28 (6): 2992-2998. DOI: 10.1245/s10434-020-09485-4
5. Kitano S, Iso Y, Moriyama M, et al. Laparoscopy-assisted Bilroth I gastrectomy. *Surg Laparosc Endosc*, 1994; 4:146-8
6. Hashizume M, Sugimachi K. Robot-assisted gastric surgery. *Surg Clin North Am*, 2003; 83: 1429-44. DOI: 10.1016/S0039-6109(03)00158-0
7. Giulianotti P C, Coratti A, Angelini M, et al. Robotics in general surgery: personal experience in a large community hospital. *Arch Surg*, 2003; 138: 777-84. DOI: 10.1001/archsurg.138.7.777

8. Zawadzki M, Witkiewicz W. Laparoscopic robotic total gastrectomy. *Videosurgery and Other Minimally Invasive Techniques*, 2014 Dec; 9 (4): 650–654. DOI: 10.5114/wiitm.2014.45128
9. Pourhoseingholi MA, Vahedi M, Baghestani A R. Burden of gastrointestinal cancer in Asia; an overview. *Gastroenterol Hepatol Bed Bench*, 2015; 8 (1): 19–27
10. Fock KM. Review article: The epidemiology and prevention of gastric cancer. *Aliment Pharmacol Ther*, 2014; 40 (3): 250–260. DOI:10.1111/apt.12814
11. Forman D, Burley V J. Gastric cancer: Global pattern of the disease and an overview of environmental risk factors. *Best Pract Res Clin Gastroenterol*, 2006; 20: 633–649. DOI: 10.1016/j.bpg.2006.04.008
12. Parisi A, Desiderio J. Establishing a multi-institutional registry to compare the outcomes of robotic, laparoscopic, and open surgery for gastric cancer. *Surgery*, 2015; 157 (4): 830–1. DOI:10.1016/j.surg.2014.12.007
13. Desiderio J, Jiang Z-W, Nguyen NT, et al. Robotic, laparoscopic and open surgery for gastric cancer compared on surgical, clinical and oncological outcomes: a multi-institutional chart review. A study protocol of the International study group on Minimally Invasive surgery for GASTRIC Cancer-IMIGASTRIC. *BMJ Open*, 2015; 5 (10): e008198. DOI:10.1136/bmjopen-2015-008198
14. <https://clinicaltrials.gov/ct2/show/study/NCT02325453>
15. Ma J, Li X, Zhao S, et al. Robotic versus laparoscopic gastrectomy for gastric cancer: a systematic review and meta-analysis. *World J Surg Oncol*, 2020; 18: 306. DOI: 10.1186/s12957-020-02080-7
16. Xinsheng Z, Weibin Z, Zhen F et al. Comparison of short-term outcomes of robotic-assisted and laparoscopic-assisted D2 gastrectomy for gastric cancer: a meta-analysis. *Videosurgery and Other Minimally Invasive Techniques*, 2021 Sep; 16 (3): 443–454. DOI: 10.5114/wiitm.2021.105731
17. Shen W, Xi H, Wei B, et al. Robotic versus laparoscopic gastrectomy for gastric cancer: comparison of short-term surgical outcomes. *Surg Endosc*, 2016; 30: 574–580. DOI: 10.1007/s00464-015-4241-7
18. Xiong B, Ma L, Zhang C. Robotic versus laparoscopic gastrectomy for gastric cancer: a meta-analysis of short outcomes. *Surg Oncol*, 2012; 21: 274–80. DOI: 10.1016/j.suronc.2012.05.004
19. Solaini L, Avanzolini A, Pacilio C A et al. Robotic surgery for gastric cancer in the west: A systematic review and meta-analyses of short-and long-term outcomes. *Int J Surg*, 2020; 83: 170–175. DOI: 10.1016/j.ijisu.2020.08.055
20. Hu LD, Li XF, Wang XY, et al. Robotic versus Laparoscopic Gastrectomy for Gastric Carcinoma: a Meta-Analysis of Efficacy and Safety. *Asian Pac J Cancer Prev*, 2016; 17: 4327–4333
21. Son T, Lee JH, Kim YM, et al. Robotic spleen-preserving total gastrectomy for gastric cancer: comparison with conventional laparoscopic procedure. *Surg Endosc*, 2014; 28: 2606–15. DOI: 10.1007/s00464-014-3511-0
22. Liu HB, Wang WJ, Li HT, et al. Robotic versus conventional laparoscopic gastrectomy for gastric cancer: A retrospective cohort study. *Int J Surg*, 2018; 55: 15–23. DOI: 10.1016/j.ijisu.2018.05.015
23. Park JM, Kim HI, Han SU, et al. Who may benefit from robotic gastrectomy?: A subgroup analysis of multicenter prospective comparative study data on robotic versus laparoscopic gastrectomy. *Eur J Surg Oncol*, 2016; 42: 1944–1949. DOI: 10.1016/j.ejso.2016.07.012
24. Lee J, Kim YM, Woo Y, et al. Robotic distal subtotal gastrectomy with D2 lymphadenectomy for gastric cancer patients with high body mass index: comparison with conventional laparoscopic distal subtotal gastrectomy with D2 lymphadenectomy. *Surg Endosc*, 2015; 29: 3251–60. DOI: 10.1007/s00464-015-4069-1
25. Zong L, Seto Y, Aikou S, et al. Efficacy evaluation of subtotal and total gastrectomies in robotic surgery for gastric cancer compared with that in open and laparoscopic resections: a meta-analysis. *PLoS One*, 2014; 9: e103312. DOI: 10.1371/journal.pone.0103312
26. Hyun MH, Lee CH, Kwon YJ, et al. Robot versus laparoscopic gastrectomy for cancer by an experienced surgeon: comparisons of surgery, complications, and surgical stress. *Ann Surg Oncol*, 2013; 20: 1258–65. DOI: 10.1245/s10434-012-2679-6
27. Huang KH, Lan YT, Fang WL et al. Comparison of the Operative Outcomes and Learning Curves between Laparoscopic and Robotic Gastrectomy for Gastric Cancer. *PLoS One*, 2014; 9: e111499. DOI: 10.1371/journal.pone.0111499
28. Yang SY, Roh KH, Kim YN, et al. Surgical Outcomes After Open, Laparoscopic, and Robotic Gastrectomy for Gastric Cancer. *Ann Surg Oncol*, 2017; 24:1770–77. DOI: 10.1245/s10434-017-5851-1
29. Huang KH, Lan YT, Fang WL ,et al. Initial Experience of Robotic Gastrectomy and Comparison with Open and Laparoscopic Gastrectomy for Gastric Cancer. *J Gastrointerst Surg* 2012; 16: 1303–10. DOI: 10.1007/s11605-012-1874-x
30. Park SS, Kim MC, Park MS, et al. Rapid adaptation of robotic gastrectomy for gastric cancer by experienced laparoscopic surgeons. *Surg Endosc*, 2012; 26: 60–7. DOI: 10.1007/s00464-011-1828-5
31. Kim HI, Park MS, Song KJ et al. Rapid and safe learning of robotic gastrectomy for gastric cancer: multidimensional analysis in a comparison with laparoscopic gastrectomy. *Eur J Surg Oncol*, 2014; 40: 1346–54. DOI: 10.1016/j.ejso.2013.09.011
32. Caruso S, Patriti A, Roviello F, et al. Robot-assisted laparoscopic vs open gastrectomy for gastric cancer: Systematic review and meta-analysis. *World J Clin Oncol*, 2017; 8: 273–284. DOI: 10.5306/wjco.v8.i3.273
33. Hyun MH, Lee CH, Kim HJ, et al. Systematic review and meta-analysis of robotic surgery compared with conventional laparoscopic and open resections for gastric carcinoma. *Br J Surg*, 2013; 100: 1566–78. DOI: 10.1002/bjs.9242