



# GIANT ANEURYSM OF THE MIDDLE CEREBRAL ARTERY TREATED BY EFFECTIVE EMBOLIZATION



Aleksandra Pogoda-Wesołowska<sup>1</sup>, Krzysztof Brzozowski<sup>2</sup>, Arkadiusz Zegadło<sup>2</sup>, Dominika Wrzesień<sup>1</sup>, Adam Stępień<sup>1</sup>

1. Wojskowy Instytut Medyczny – Państwowy Instytut Badawczy, Klinika Neurologiczna, Polska
2. Wojskowy Instytut Medyczny – Państwowy Instytut Badawczy, Zakład Radiologii Lekarskiej, Polska

**Abstract:** Giant aneurysms (GA) of middle cerebral artery (MCA) are rare and account for approximately 0.5-4.8% of intracranial artery aneurysms. Early diagnosis of brain GA is critical. Classic digital subtraction angiography (DSA) with the option of three-dimensional rotational angiography remains the “gold standard” in the diagnosis of intracranial aneurysms, including GA. The primary goal of brain GA treatment is to permanently exclude the aneurysm from the circulation while preserving the flow in the candelabra. The secondary goal is to stop the growth of the aneurysm and reduce the ‘mass effect’ symptoms it causes. Despite new endovascular techniques and advances in microsurgery, the treatment of GA MCA is still a therapeutic challenge. There are only a few reports in the literature describing cases of patients diagnosed with GAs of MCA and evaluating various treatment methods. In this article, we present the case of a 78-year-old patient with GA of the right MCA, who underwent effective embolization of the active part of the aneurysm.

**Keywords:** embolization, case report, endovascular treatment, middle cerebral artery, giant aneurysm.

DOI 10.53301/lw/171872

Received: 2023.07.30

Accepted: 2023.09.05

## Corresponding author:

Aleksandra Bernadeta Pogoda-Wesołowska  
Wojskowy Instytut Medyczny – Państwowy Instytut  
Badawczy, Klinika Neurologiczna, Warszawa  
e-mail: olapogodaa@gmail.com

## Introduction

Intracranial artery aneurysms are the most common type of cerebral vascular malformations [1]. They occur in 2.8% (95% CI, 2.0-3.9%) of the human population and in 85% of cases are located in the anterior part of the arterial circle of Willis [2-4].

Proven risk factors for the occurrence and rupture of intracranial aneurysms include age, female gender, smoking, alcoholism, hypertension, hyperlipidemia, hyperglycemia, family history of polycystic kidney disease or subarachnoid hemorrhage (SAH), as well as the presence of aneurysms in at least two relatives [5-6]. Other risk factors for the development of aneurysms include connective tissue disorders such as Ehlers-Danlos syndrome, head injury, infection or birth defects. In addition, it has been shown that the presence and intensity of the inflammatory process may be more important in the process of aneurysm rupture than its size and location [7].

Symptoms of aneurysms may suggest the presence of a brain tumor, resulting from the mass effect (headaches and dizziness, seizures, nausea and vomiting, visual disturbances, or symptoms of focal damage to the central nervous system (CNS) i.e. cranial nerve palsy, hemiparesis, dysphagia or aphasia), especially with large or giant aneurysms (GA) [8].

GA of middle cerebral artery (MCA) with a diameter greater than 2.5 cm are rare and account for approximately 0.5-4.8% of all diagnoses [9-13]. They can develop de novo in defective areas of the internal elastic lamina or evolve from smaller aneurysms under constant hemodynamic stress [14]. Most of them are saccular type. The pathogenesis of intracranial aneurysms are influenced by a number of risk factors, including genetic variables as proven by higher frequency of aneurysms in some hereditary diseases, including polycystic kidney disease and familial aggregation [15]. Familial aneurysms account 5.1% in population of giant aneurysms [16]. The study of Khurana et al. showed that all patients with large ruptured aneurysm were heterozygous for the endothelial nitric oxide synthase (eNOS) [17]. However, a study conducted by Huttunen et al. showed no correlation between aneurysm size and rupture age, suggesting that aneurysm size is mainly a consequence of hemodynamic stress [18].

Early diagnosis of brain GA is critical. In brain computed tomography (CT), GA appears as a well-circumscribed, circular or lobular, slightly hyperdense lesion, often manifesting a “mass effect” [14]. CT in the vascular option with the use of contrast (angio-CT) is the most frequently performed examination in the diagnosis of intracranial aneurysms. However, classic digital subtraction angiography (DSA) with the option of three-dimensional

rotational angiography remains the “gold standard” in the diagnosis of intracranial aneurysms [19].

The primary goal of brain GA treatment is to permanently exclude the aneurysm from the circulation while preserving the flow in the candelabra. The secondary goal is to stop the growth of the aneurysm and reduce the ‘mass effect’ symptoms it causes.

Despite new endovascular techniques and advances in microsurgery, the treatment of GA MCA is still a therapeutic challenge, which is additionally often complicated by technical difficulties, such as the fusiform shape, thrombi in the aneurysm sac, atherosclerosis and calcification of the arterial walls, the presence of candelabra or involvement of the M1 segment [20-21].

In this article, we present the case of a 78-year-old patient with GA of the right MCA, who underwent effective embolization of the active part of the aneurysm.

### Case report

The 78-year-old patient was admitted urgently to the Neurological Clinic of the Military Institute of Medicine - National Research Institute (MIM-NRI) in July 2022 due to speech disorders, impaired coordination and balance, psychomotor retardation and periodic problems with concentration and memory. Symptoms started about a year earlier and gradually worsened. The ambulatory performed CT examination of the brain showed partially hyperdense, focal lesion in the middle cranial fossa size of 59 x 54 x 55 mm, containing annular calcifications. It infiltrated the sphenoid bone and the left temporal bone and caused a “mass effect” [Fig. 1 A]. The patient was under the constant care of the Surgical Clinic due to an aneurysm dilatation of the abdominal aorta to 45 mm at a length of 6 cm below the origin of the renal arteries. The past medical history also included hypertension, hyperlipidemia, prostatic hyperplasia, status after surgical treatment of glaucoma and cataracts (2021), status after surgical treatment of the cervical spine (1997).

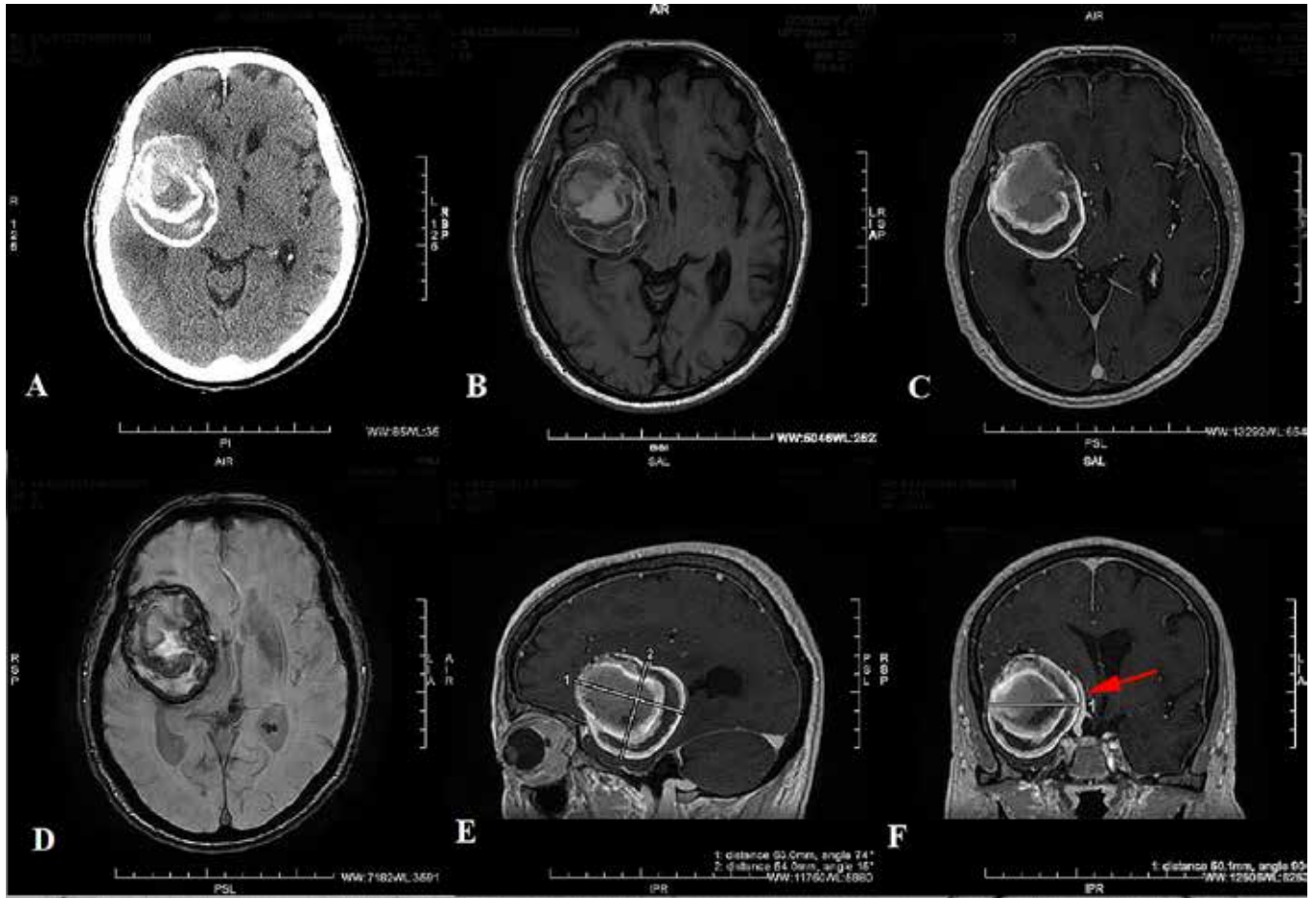
The neurological examination on admission showed central paresis of facial nerve on the left side (the patient could not precisely determine the time of onset of the symptom), slight dysarthria and insecurity during gait. Magnetic resonance imaging (MRI) examination of the brain, performed during hospitalization, revealed a GA of the right MCA in the middle cranial fossa size of 63x50mm in transverse dimensions and 54 mm in longitudinal dimensions, causing a “mass effect” with swelling of the brain tissue up to 25 mm wide [Fig. 1 B-F]. In addition, multifocal vascular brain injury has been described. After consultation with an interventional radiologist the brain DSA including a 3D examination of the right ICA was performed. Its result confirmed the presence of the GA right MCA [Fig. 2 A]. The aneurysm was completely filled with thrombi and calcifications with an active aneurysm neck, the size of which was 5.8 x 3.8 mm. The right MCA and its candelabras were lifted up and profiled by the mass of the aneurysm. The patient was consulted by an ophthalmologist - no edema of the optic discs was found during the examination of the fundus. He did not require antiplatelet therapy before the procedure, be-

cause the implantation of a brain stent was not planned. After cardiological consultation and modification of anti-hypertensive treatment on July 7 2022 the embolization of the active part of the right MCA segment M1/2 aneurysm with the use of cerebral embolization spirals was performed in the Interventional Radiology Laboratory of the MIM-NRI [Fig. 2 B-C]. The course of the procedure was without complications. After embolization, the patient was recommended to control blood pressure and take statins. The patient was consulted by neurosurgeon and qualified for surgical treatment: resection of the aneurysm by craniotomy.

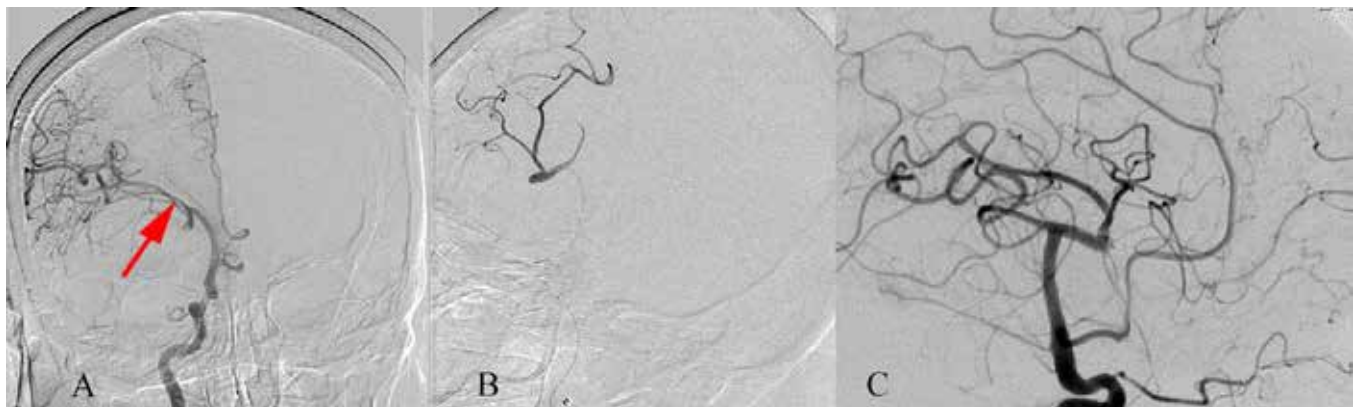
During hospitalization, patients was treated with anti-edematous drugs (dexamethasone and mannitol). Due to the EEG recording with single sharp waves with a slow one in the right temporal region, he received also anti-epileptic treatment (sodium valproate). In good general condition patient was discharged home with the recommendation to take antiepileptic treatment and perform a blood pressure 24hours monitoring before the planned neurosurgical procedure.

In October 2022. the patient was admitted to the Neurosurgical Clinic of the MIM-NRI. On admission, the patient was in good neurological condition; Glasgow Coma Scale (GCS) score at 15 points, discrete central paresis of the left facial nerve was observed. Due to the sustained significant improvement in the patient's functioning and the fact that the active part of the aneurysm was properly embolized, as well as because of the high risk of surgical treatment, surgery was finally abandoned. The follow-up cerebral arteriography was recommended in about 6 months. In November 2022 the patient underwent a follow-up visit at the Neurological Clinic of the MIM-NRI. During the visit, the patient's condition and mood were good, he did not report any new ailments, however, a discreet central paresis of the left facial nerve persisted. The follow-up MRI examination with contrast was recommended, as well as angio-MR, in which embolization coils were visualized in the neck of the aneurysm. There was no flow signal or contrast within the aneurysm [Fig 3 D-F]. No significant dynamics in the size of the aneurysm sac was observed. In May 2023 the patient was admitted to the Neurosurgical Clinic of the MIM-NRI for follow-up DSA. On admission, the patient was in good neurological condition, discrete central paresis of the left facial nerve was still present. From puncture of the right radial artery under local anesthesia, a selective angiography of the right cerebral hemisphere was performed, revealing an image comparable to the postoperative examination in July 2022. This confirmed that good effect of the treatment was maintained. Due to the correct embolization of the active part of the aneurysm, lack of progression of changes in the radiological image and stable clinical condition of patient, conservative treatment and regular neurological/neurosurgical follow-up visits were recommended.

**Figure 1.** Baseline imaging examinations. (A) The brain CT scan from 27 June 2022 showed the presence of a pathological mass in the middle cranial fossa of the right brain hemisphere. MRI examination performed on 29 June 2022 revealed a GA with size of 63 x 54 x 50.1 mm with a layered thrombus. (B) Sequence Ax T2 FLAIR, (C) +C ax3DT1, (D) Obl.3D SWAN, (E) Obl. sag T2 Prope, (F) Obl.cor.T2 Prope. (B) MRI showing lesion morphology, (C) nature of vascularization, (D) presence of hemoglobin deposits, (E, F) size and location.

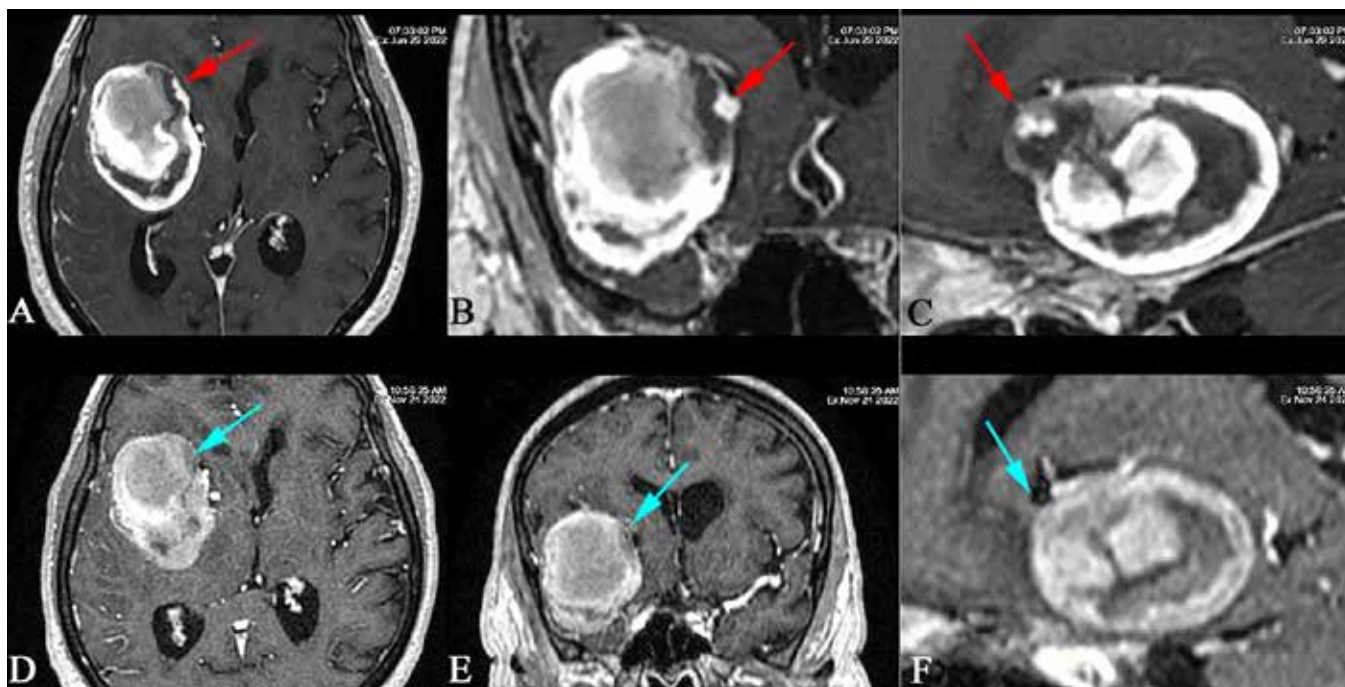


**Figure 2.** Classic digital subtraction angiography examination. A) The A-P projection shows the 'mass effect' of the GA in the form of ICA and MCA modeling on the GA bag. (B) Administration of a contrast agent through a microcatheter to the active part of the aneurysm. (C) Condition after coil embolization of the active part of the aneurysm.





**Figure 3.** MRI examination with intravenous contrast agent, T1-weighted sequences in axial (A, B), coronalis (B, D) and sagittal (C, F) projections. GA replenishment site from the RMCA side in the MRI from 29 June 2022 was marked with a red arrows (A, B, C). The follow up MRI examination performed on 24 November 2022 showed effective embolization of the active part of GA marked with blue arrows (D, E, F).



## Discussion

The dominant clinical symptoms in patients with GAs (i.e. headaches, seizures and features of focal CNS damage) are related to the mass effect [22]. In addition, the large size of GAs, their irregular shape, heterogeneous enhancement and edema of the brain tissue visible around the lesion, may often be misinterpreted as a brain tumor in imaging tests such as CT or MRI.

Untreated intracranial GAs have a 5-year mortality rate > 80% due to the high risk of subarachnoid hemorrhage and the progressive mass effect [14]. The aim of treatment of intracranial aneurysms is to exclude them from the circulation and protect the patient against recurrent hemorrhage, i.e. the consequences of intracranial bleeding. Currently, there are two methods of treatment available such as surgery and endovascular treatment, which can be performed together or separately [8].

Endovascular treatment requires appropriate equipment - angiograph, as well as catheters and microcatheters of very small dimensions. Endovascular aneurysm embolization procedures are performed with the use of X-rays and iodine contrast agents. This method consists in inserting an appropriate set of microcoils inside the aneurysm sac and filling it with special coils or dedicated devices to exclude the aneurysm from the cerebral circulation. Currently, stents are used to redirect the blood and reduce blood flow to the aneurysm. There are also methods of combining both coils and stents simultaneously in the procedure. In case of the use of brain stents, the patient should take double antiplatelet therapy (clopidogrel+ acetylsalicylic acid or brilique + acetylsalicylic acid) to prevent clotting in the implanted stent. In our

case, there was no such need, because only embolization coils were used. After excluding the aneurysm from the circulation, anticoagulation can be used in the case of, among others, cardiac indications, e.g. atrial fibrillation. Results from research conducted by Hanada et al. suggest that in patients requiring oral anticoagulants, direct oral anticoagulant (DOACs) may be more beneficial than vitamin K antagonists (VKA) for preventing stroke occurrences after endovascular treatment [23].

Considering their large size, localization and morphology (absence of aneurysm neck and dependent distal vessels), GAs pose a technical challenge and still cause great difficulties during endovascular procedures. These are aneurysms with the highest rate of recanalization and often require repeated treatment, frequently incomplete and complicated, both during and after the procedure [24]. In addition, although cerebral arteries are relatively constant in their anatomy, there are individual differences that should be kept in mind before treatment.

There are only a few reports in the literature describing cases of patients diagnosed with GAs of MCA and evaluating various treatment methods. Sadik et al. described a fusiform, partially thrombotic MCA aneurysm of more than 8 cm in size, in a patient who died after an exploratory craniotomy [25]. Drake noted that among 9 cases of GAs neurosurgical treatment published in the years 1965-1977 by various authors, 4 patients (44%) died [26]. In recent reports, in which microsurgical treatment was preferred, postoperative complications occurred in 23.3%-60% of patients [9, 11]. In study by Pilipenko et al. aneurysm clipping was the most common therapeutic intervention, followed by bypass surgery and endovascular treatment [27]. Neurological deterioration in

the perioperative period was observed in 50.9% of patients, and mortality was 1.8%. Complete closure of the aneurysm was achieved in 78.2%. The long-term outcome was favorable in 76.9% of patients. Mortality including long-term follow-up was 9.4%. Recurrent GAs MCA after surgery was observed in 3.6% of patients. The most common complication was acute ischemic stroke (AIS) (80% of cases). Park et al. also showed, that AIS was the most common complication associated with neurosurgical treatment of GAs MCA [9]. In their study aneurysm clipping was the most common therapeutic method, followed by vascular bypass and endovascular treatment. 60% of patients experienced one or more procedural and/or SAH-related complications. According to various authors, AIS in the postoperative period after GAs MCA treatment occurred in 14–25% [9, 12, 28-29].

After surgical treatment, the size of GA may be stable or increase over time. Therefore, each growing residual aneurysm should be considered an indication for a second intervention [9, 30].

Prior to initiating therapeutic management, it should be individually tailored to each clinical case, taking into account the risk factors for adverse outcomes. The decision on the choice of treatment should be preceded by an analysis of clinical condition, the results of imaging examinations and the experience of treating team. In the case of patient described in this article, the probability of an adverse outcome of the neurosurgical procedure outweighed the long-term risk of aneurysm rupture. In addition, the patient's good clinical condition and advanced age were the main reasons for abandoning surgery in favor of endovascular treatment.

As mentioned earlier, the patient was under constant care of the Surgical Clinic due to an aneurysm dilatation of the abdominal aorta. A study conducted by Rouchaud et al. showed, that prevalence of associated intracranial aneurysms in patients with abdominal aortic aneurysms was 11.8% (128/1081) [31]. There was a slight association between abdominal aortic aneurysm size and the prevalence of intracranial aneurysms. There was no significant association between the locations of aortic and intracranial aneurysms. Similarly, a study by Erben et al. showed that the co-prevalence of intracranial aneurysms among patients with abdominal aortic aneurysms was more than three times the rate seen in patients without abdominal aortic aneurysms [32]. In addition, Kurtelius et al. found, that prevalence of aortic aneurysms is increased significantly in patients with fusiform intracranial aneurysms and slightly in patients with saccular intracranial aneurysms [33]. The authors recommend screening patients with fusiform intracranial aneurysms for aortic aneurysms. However, based on our observations, the percentage of such cases is small. According to opinion of vascular surgeons of the MIM-NRI, screening for CNS aneurysm is not normally performed in patients with history of aortic aneurysm. In the case of coexistence of aneurysms in different locations, periodic imaging tests, e.g. angio-CT or Doppler ultrasound, should be performed.

Based on previous reports from the medical literature, case reports of the occurrence and treatment of GA

still belong to casuistry. Currently, the main challenges requiring further research are introduction of new precise diagnostic methods for the assessment of collateral flow and long-term evaluation of both endovascular treatment results and combination methods. Careful follow-up of patients in the long term after surgery and control angiographic examinations are very important. The relative rarity of GA MCA necessitates multicenter studies and published case reports. Such work could increase the reliability of the collected data and improve patients' outcomes.

## References

1. Knap D, Partyka R, Zbroszczyk M, Korzekwa M, Zawadzki M, Gruszczyńska K, Baron J. Tętniaki mózgu - współczesne metody leczenia wewnątrznaczyniowego, 26 Polski Przegląd Neurologiczny, 2010; tom 6, nr 1
2. Kumar VC R., Robbins S. Patologia. Wrocław 2005
3. Mascitelli JR, Moyle H, Oermann EK, et al. An update to the Raymond-Roy Occlusion Classification of intracranial aneurysms treated with coil embolization. *J Neurointerv Surg.* Jul 2015; 7 (7): 496-502
4. Vlak MH, Algra A, Brandenburg R, Rinkel GJ. Prevalence of unruptured intracranial aneurysms, with emphasis on sex, age, comorbidity, country, and time period: a systematic review and meta-analysis. *Lancet Neurol.* Jul 2011; 10 (7): 626-636
5. Raaymakers TW. Aneurysms in relatives of patients with subarachnoid hemorrhage: frequency and risk factors. MARS Study Group. *Magnetic Resonance Angiography in Relatives of patients with Subarachnoid hemorrhage.* *Neurologym.* Sep 22 1999; 53 (5): 982-988
6. Krings T, Mandell DM, Kiehl TR, et al. Intracranial aneurysms: from vessel wall pathology to therapeutic approach. *Nat Rev Neurol.* Sep 20 2011; 7 (10): 547-559
7. Zhang HF, Zhao MG, Liang GB, Song ZQ, Li ZQ. Expression of pro-inflammatory cytokines and the risk of intracranial aneurysm. *Inflammation.* Dec 2013; 36 (6): 1195-1200
8. Al Shamy A.M., Alshafi M.D., Alghamdi M.A., Alshamrani A.A., Filfilan R.A. Giant Serpentine Cerebral Aneurysm of the Middle Cerebral Artery: Case Report. *Open Journal of Medical Imaging.* Vol.7 No.1, March 2017
9. Park W, Chung J, Ahn JS, Park JC, Kwun BD. Treatment of large and giant middle cerebral artery aneurysms: risk factors for unfavorable outcomes. *World Neurosurg.* 2017; 102: 301-312
10. Rinne J, Hernesniemi J, Niskanen M, Vapalahti M. Analysis of 561 patients with 690 middle cerebral artery aneurysms: anatomic and clinical features as correlated to management outcome. *Neurosurgery.* 1996; 38: 2-11
11. Rodríguez-Hernández A, Sughrue ME, Akhavan S, Habdank-Kolaczowski J, Lawton MT. Current management of middle cerebral artery aneurysms: surgical results with a clip first policy. *Neurosurg.* 2013; 72: 415-427
12. Kivipelto L, Niemela M, Meling T, Lehecka M, Lehto H, Hernesniemi J. Bypass surgery for complex middle cerebral artery aneurysms: impact of the exact location in the MCA tree. *J Neurosurg.* 2014; 120: 398-408
13. Nurminen V, Lehecka M, Chakrabarty A, et al. Anatomy and morphology of giant aneurysms - angiographic study of 125 consecutive cases. *Acta Neurochir (Wien).* 2014; 156: 1-10
14. Giant intracranial aneurysm of the right middle cerebral artery Kunal Kulkarni, Afroze Khan, Zishan Sheikh, Abbas Khan, Ramesh Nair QJM: An International Journal of

- Medicine, Volume 106, Issue 4, April 2013; 375–376
15. Roos YB, Pals G, Struycken PM, Rinkel GJ, Limburg M, Pronk JC, et al. Genome-wide linkage in a large Dutch consanguineous family maps a locus for intracranial aneurysms to chromosome 2p13. *Stroke*, 2004; 35: 2276–81
  16. Derrey S, Penchet G, Thines L, Lonjon M, David P, Emery E, et al. French collaborative group series on giant intracranial aneurysms: current management. *Neurochirurgie*, 2014
  17. Khurana VG, Sohni YR, Mangrum WI, McClelland RL, O’Kane DJ, Meyer FB, et al. Endothelial nitric oxide synthase T-786C single nucleotide polymorphism: a putative genetic marker differentiating small versus large ruptured intracranial aneurysms. *Stroke*, 2003; 34: 2555–9
  18. Huttunen T, von und zu Fraunberg M, Frosen J, Lehecka M, Tromp G, Helin K, et al. Saccular intracranial aneurysm disease: distribution of site, size, and age suggests different etiologies for aneurysm formation and rupture in 316 familial and 1454 sporadic eastern Finnish patients. *Neurosurgery*, 2010; 66: 631–8
  19. Lan J, Fu Z, Zhang J, Ma C, Cao C, Zhao W, Jiang P, Chen J, Giant Serpentine Aneurysm of the Middle Cerebral Artery. *World Neurosurgery*, 2018; 31201-4
  20. Andaluz N, Zuccarello M. Treatment strategies for complex intracranial aneurysms: review of a 12- year experience at the University of Cincinnati. *Skull Base*, 2011; 21: 233-241
  21. Hanel RA, Spetzler RF. Surgical treatment of complex intracranial aneurysms. *Neurosurgery*, 2008; 62 (6 suppl): 1289-1299
  22. Finlay HM, Whittaker P, Canham PB. Collagen organization in the branching region of human brain arteries. *Stroke*, Aug 1998; 29 (8): 1595-1601
  23. Hayatsura Hanada,1,2 Kouhei Nii,1,2 Kimiya Sakamoto,1 Ritsuro Inoue,1 Yoko Hirata,1 Kodai Matsuda,1 Jun Tsugawa,3 Sho Takeshita,3 Sachiko Shirakawa,3 and Toshio Higashi1,2; Analysis of Cerebrovascular Events after Coil Embolization of Unruptured Cerebral Aneurysms in Patients Taking Anticoagulants. *Journal of Neuroendovascular Therapy Advance* Published Date: January 13, 2023
  24. Marques-Sanches P, et al. Aneurysms of The Middle Cerebral Artery Proximal Segment (M1), Anatomical and Therapeutic Considerations · Revision of A Series. Analysis of a series of the pre bifurcation segment aneurysms. *Asian J Neurosurg*, 2010
  25. Sadik AR, Budzilovich GN, Shulman K. Giant aneurysm of middle cerebral artery: a case report. *J Neurosurg*, 1965; 22: 177-181
  26. Drake CG. Giant intracranial aneurysms: experience with surgical treatment in 174 patients. *Clin Neurosurg*, 1979; 26: 12-95
  27. Pilipenko Y, Eliava S, Abramyan A, Grebenev F, Birg T, Kheireddin A, Shekhtman O and Arustamyan S. Giant Middle Cerebral Artery Aneurysms: A 55-Patient Series. *World Neurosurgery*, 2021; 155: e727-e737
  28. Zhu W, Liu P, Tian Y, et al. Complex middle cerebral artery aneurysms: a new classification based on the angioarchitecture and surgical strategies. *Acta Neurochir (Wien)*, 2013; 155: 1481-1491
  29. Natarajan SK, Zeeshan Q, Ghodke BV, Sekhar LN. Brain bypass surgery for complex middle cerebral artery aneurysms: evolving techniques, results, and lessons learned. *World Neurosurg*, 2019; 130: e272-e293
  30. David CA, Vishteh AG, Spetzler RF, Lemole M, Lawton MT, Partovi S. Late angiographic follow-up review of surgically treated aneurysms. *J Neurosurg*, 1999; 91: 396-401
  31. Rouchaud A, Brandt A, Rydberg R, Kadirvel K, Flemming, Kallmes D, Brinjikja W, Prevalence of Intracranial Aneurysms in Patients with Aortic Aneurysms. *AJNR Am J Neuroradiol*, 2016 Sep; 37 (9): 1664–1668
  32. Erben Y, Da Rocha-Franco JA, Ball CT, Barrett KM, Freeman WD, Lin M, Tawk R, Huang JF, Vibhute P, Oderich G, Miller DA, Farres H, Davila V, Money SR, Meltzer AJ, Hakaim AG, Brott TG, Meschia JF. Prevalence of Intracranial Aneurysms in Patients with Infrarenal Abdominal Aortic Aneurysms: A Multicenter Experience. *Int J Angiol*, 2020; 29 (04): 229-236
  33. Kurtelius A, Vääntti N, Jahromi BR, Tähtinen O, Manninen H, Koskenvuo J, Tulamo R, Kotikoski S, Nurmonen H, Kämäräinen O-P, Huttunen T, Huttunen J, von und zu Fraunberg M, Koivisto T, Jääskeläinen JE, Lindgren AE. Association of Intracranial Aneurysms With Aortic Aneurysms in 125 Patients With Fusiform and 4253 Patients With Saccular Intracranial Aneurysms and Their Family Members and Population Controls. *J Am Heart Assoc*, 2019 Sep 17; 8 (18): e013277