



PERSONALIZED TEMPOROMANDIBULAR JOINT ENDOPROSTHESES – OWN EXPERIENCE

Spersonalizowane endoprotezy stawu skroniowo-
-żuchwowego – własne doświadczenia



Iwona Niedzielska¹, Julia Maślanka², Jakub Fiegler-Rudol², Daria Wziątek-Kuczmik¹

1. Department and Clinic of Cranio-Maxillofacial Surgery, Medical University of Silesia in Katowice, Poland
2. Student Scientific Club at the Department and Clinic of Cranio-Maxillofacial Surgery, Medical University of Silesia in Katowice, Poland

Iwona Niedzielska –  0000-0003-1256-9408

Julia Maślanka –  0009-0009-8049-0831

Jakub Fiegler-Rudol –  0009-0009-3173-9389

Daria Wziątek-Kuczmik –  0000-0002-5720-6419

Abstract

Background: Temporomandibular joint disorders can severely impair mandibular function, aesthetics, and quality of life. When conservative management fails, temporomandibular joint replacement with patient-specific, custom-made prostheses provides a reliable surgical solution. However, the success of such interventions depends not only on surgical precision but also on comprehensive prehabilitation and rehabilitation. **Objective:** This study presents a case series highlighting the critical role of individualized rehabilitation in optimizing outcomes after temporomandibular joint replacement. **Materials and methods:** Three patients with advanced temporomandibular joint pathology, a comminuted condylar fracture, bilateral temporomandibular joint ankylosis, and mandibular ameloblastoma, underwent reconstruction with custom implants. Each patient participated in a structured prehabilitation program, including physiotherapy, laser therapy, and myofascial release, followed by an individualized postoperative rehabilitation protocol. **Results:** All patients achieved significant functional recovery, including improved mandibular mobility, mastication, swallowing, and speech, as well as complete pain resolution and restoration of facial symmetry. The multidisciplinary rehabilitation approach was instrumental in accelerating recovery and enhancing quality of life. **Conclusion:** Temporomandibular joint replacement with custom-made prostheses, combined with a protocol-driven prehabilitation and rehabilitation program, ensures optimal functional and aesthetic outcomes. This case series emphasizes that rehabilitation is not an adjunct but an essential, integral component of successful temporomandibular joint reconstruction.

Streszczenie

Wprowadzenie: Zaburzenia stawu skroniowo-żuchwowego mogą poważnie upośledzać funkcję żuchwy, estetykę oraz jakość życia. W przypadkach, gdy leczenie zachowawcze nie przynosi efektów, wymiana stawu na spersonalizowaną, indywidualnie wykonaną endoprotezę stanowi wiarygodne rozwiązanie chirurgiczne. Skuteczność takich interwencji zależy jednak nie tylko od precyzji operacyjnej, lecz także od kompleksowej strategii prehabilitacji i rehabilitacji. **Cel:** Celem pracy jest przedstawienie serii przypadków, które podkreślają kluczową rolę indywidualnej rehabilitacji w optymalizacji wyników leczenia po wymianie stawu skroniowo-żuchwowego. **Materiał i metody:** Trzech pacjentów z zaawansowaną patologią stawu skroniowo-żuchwowego, roztrzaskanym złamaniem wyrostka kłykciowego, obustronną ankylozą stawu oraz ameloblastomą żuchwy, poddano rekonstrukcji stawu przy użyciu indywidualnie zaprojektowanych implantów. Każdy z pacjentów uczestniczył w ustrukturyzowanym programie prehabilitacji, obejmującym fizjoterapię, laseroterapię oraz uwalnianie mięśniowo-powięziowe, a następnie realizował spersonalizowany protokół rehabilitacji pooperacyjnej. **Wyniki:** U wszystkich pacjentów odnotowano istotną poprawę funkcjonalną, w tym zwiększenie ruchomości żuchwy, poprawę żucia, połykania i mowy, całkowite ustąpienie bólu oraz przywrócenie symetrii twarzy. Wielospecjalistyczne podejście rehabilitacyjne odegrało kluczową rolę w przyspieszeniu procesu powrotu do zdrowia i poprawie jakości życia. **Wniosek:** Wymiana stawu skroniowo-żuchwowego przy użyciu indywidualnych endoprotez, połączona z protokolowym programem prehabilitacji i rehabilitacji, zapewnia optymalne efekty funkcjonalne i estetyczne. Przedstawione przypadki podkreślają, że rehabilitacja nie jest dodatkiem, lecz nieodzownym i integralnym elementem skutecznej rekonstrukcji stawu skroniowo-żuchwowego.

Keywords: prehabilitation; physiotherapy; postoperative rehabilitation; temporomandibular joint disorders

Słowa kluczowe: prehabilitacja; fizjoterapia; rehabilitacja pooperacyjna; zaburzenia stawu skroniowo-żuchwowego

DOI 10.53301/lw/209432

Received: 28.07.2025

Accepted: 12.08.2025

Opublikowano: 30.12.2025

Introduction

Temporomandibular joint (TMJ) disorders include a broad spectrum of conditions affecting the jaw joint and surrounding muscles, frequently resulting in notable disruption of both function and facial harmony [1–3]. These conditions may lead to persistent discomfort, restricted jaw mobility, and difficulties with basic actions such as chewing, speaking, or swallowing, all of which can significantly degrade a patient's overall well-being [4]. In many cases, the chronic nature of these symptoms contributes to anxiety, sleep disturbances, and reduced productivity, amplifying their social and economic impact. Beyond the physical manifestations, the psychological burden, driven by facial imbalance, ongoing pain, and reduced social confidence, can be equally profound [5]. TMJ dysfunction arises from multiple causes such as physical injury, developmental anomalies, autoimmune or infectious diseases, systemic conditions such as rheumatoid arthritis, or age-related degeneration [6]. Emerging research also suggests a possible link between TMJ disorders and neurogenic inflammation, pointing to novel pathways for future therapeutic intervention. In advanced or treatment-resistant cases, where noninvasive therapies fail, surgical reconstruction becomes a necessary path forward [6]. A cutting-edge solution involves total joint replacement using custom-engineered, patient-specific implants [7]. These precision-designed prostheses closely replicate the anatomical structure and biomechanical behavior of the natural joint, offering enhanced outcomes in terms of joint stability, mobility, and aesthetic restoration [8]. Recent advances in computer-aided design (CAD) and 3D printing have revolutionized the production of these implants, allowing for greater customization and faster surgical planning. Nevertheless, surgical replacement represents only one component of comprehensive care. Long-term success depends on a robust rehabilitation strategy that begins preoperatively (prehabilitation) and extends well beyond surgery [9]. This integrative approach is vital for enhancing procedural outcomes, reducing postoperative complications, and facilitating complete functional recovery [10]. Additionally, incorporating tele-rehabilitation and digital monitoring tools has shown promise in improving patient adherence and allowing real-time feedback during recovery. At the Department of Craniofacial and Maxillofacial Surgery in Katowice, TMJ disorders are managed through a patient-centered, holistic care model. A dedicated rehabilitation team collaborates closely with surgeons, physiotherapists, and specialists to support the patient throughout all stages of recovery. From accurate diagnosis to full reintegration into daily life, this coordinated approach helps patients not only regain physical functionality but also rebuild confidence and psychosocial well-being. The integration of mental health support and patient education further empowers individuals to actively partici-

Corresponding author:

Jakub Fiegler-Rudol
Student Scientific Club at the Department
and Clinic of Cranio-Maxillofacial Surgery,
Medical University of Silesia in Katowice, Poland
e-mail: jakub.fieglerrudol@gmail.com

pate in their recovery journey, making the process more sustainable and effective. The aim of this case series is to showcase an integrative pathway to TMJ replacement, emphasizing the transformative impact of personalized rehabilitation. By presenting detailed clinical cases, we highlight the depth of multidisciplinary coordination necessary for successful outcomes in TMJ reconstruction. Each case underscores the importance of tailoring rehabilitation not only to anatomical needs but also to the patient's lifestyle, goals, and psychological resilience. This report adheres to the recommendations outlined in "Guidelines To Writing A Clinical Case Report" published in *Heart Views: The Official Journal of the Gulf Heart Association* [10], which stress the importance of structured narrative, rich clinical detail, and analytical commentary to maximize educational and clinical value. This article introduces an innovative, patient-centered framework for TMJ replacement that integrates customized 3D-printed implants, prehabilitation, and digital rehabilitation tools, highlighting the transformative impact of multidisciplinary care on both functional recovery and psychosocial outcomes.

Materials and methods

This case series, conducted at the Department of Craniofacial and Maxillofacial Surgery, Medical University of Silesia in Katowice, Poland, included three patients with advanced mandibular pathology requiring reconstruction using custom-made endoprostheses. All patients underwent comprehensive diagnostics, including CT and panoramic radiographs, to assess joint damage and guide implant design. Inclusion criteria encompassed TMJ pathologies unsuitable for standard surgery, such as multifragmentary condylar fractures, bilateral ankylosis, or extensive neoplastic lesions requiring joint replacement. Before surgery, patients completed a structured prehabilitation program, which included physiotherapy, myofascial release, stretching, education, and low-level laser therapy. Surgical planning was performed using digital modeling in collaboration with engineers, followed by surgery under general anesthesia. Each patient followed an individualized postoperative rehabilitation protocol with Bioptron and laser therapy, TheraBite®-assisted mobilization, electrostimulation, and kinesioteaping. Outcomes were assessed based on improvements in mobility, pain, symmetry, and overall function, demonstrating the effectiveness of this multimodal approach to TMJ replacement.

Cases

Case 1. Multifragmentary fracture of the condylar process of the mandible on the left side

A 32-year-old woman presented to our unit with a multifragmentary fracture of the left condylar process of the

mandible following facial trauma sustained during an assault under unknown circumstances. Initially managed conservatively at another facility, she continued to experience severe pain, significant restriction of mandibular movement, malocclusion, and visible facial asymmetry. Clinical examination revealed tenderness and swelling over the left TMJ with markedly limited mouth opening. CT imaging confirmed a comminuted fracture of the left condylar head with displacement and shortening.

Due to the extent of fragmentation and prior unsatisfactory outcomes with conservative treatment, surgical fixation was not feasible. In 2018, she underwent condylectomy of the left mandibular condylar process with stable osteosynthesis of the mandibular ramus fragments. Postoperatively, she was followed at our outpatient clinic, where persistent issues were noted, including significantly restricted mouth opening and an anterior open bite. Intensive rehabilitation led to partial improvement in occlusion and mandibular abduction; however, the patient continued to report chronic pain localized to the left TMJ area, radiating across the cheek, and aggravated by mastication of hard foods. Given the functional impairment and ongoing symptoms, the decision was made to proceed with delayed TMJ reconstruction using a custom-made endoprosthesis. After necessary preoperative preparations, in 2023, the patient underwent endoprosthetic replacement of the left TMJ under general anesthesia via combined Al-Kayat–Bramley and submandibular approaches. A custom-designed ChM implant was used, achieving the planned mandibular position and a postoperative mouth opening of 32 mm. The perioperative and postoperative courses were uneventful, and the patient was discharged home with appropriate postoperative care instructions. Following surgery and structured rehabilitation, she experienced significant functional improvement, pain relief, and restoration of facial symmetry.

Figure 1 shows the preoperative documentation and planning for TMJ reconstruction. The figure illustrates

the diagnostic and planning stages for temporomandibular joint (TMJ) replacement in a patient with advanced mandibular pathology. The left column (Patient) shows clinical photographs of the patient's profile and restricted mouth opening, indicative of impaired TMJ function. The middle column (CT) presents a coronal CT slice and a 3D CT reconstruction, revealing bilateral condylar damage and anatomical distortion. The right column (Treatment plan) shows digital planning models for the design of patient-specific, custom-made alloplastic TMJ prostheses. The virtual reconstruction includes fixation plates and prosthetic components tailored to the patient's unique anatomy (Fig. 1).

Case 2. Bilateral ankylosis of the temporomandibular joints

A 45-year-old woman presented with a complex, long-standing clinical history beginning in 1989, when she developed mandibular osteitis secondary to a gangrenous deciduous tooth. Initial management included systemic antibiotic therapy and multiple surgical debridement sessions aimed at controlling the infection and preserving mandibular structure. Despite these interventions, the patient experienced ongoing complications, leading to progressive mandibular dysfunction over the years.

In 2006, due to persistent chronic inflammation and bone sclerosis, she underwent surgical decortication of the right mandibular angle. However, disease progression continued, culminating in the development of bilateral TMJ ankylosis. In 2011, a major surgical procedure was performed to release the ankylosis, involving bilateral excision of ankylosed bone blocks affecting both the mandibular condyles and the adjacent temporal bones. At the time of referral, physical examination demonstrated severely restricted maximal incisal opening (approximately 5–10 mm), significant facial asymmetry, and extensive post-surgical scarring along the lower face. Palpation revealed rigid, immobile TMJs, with substan-

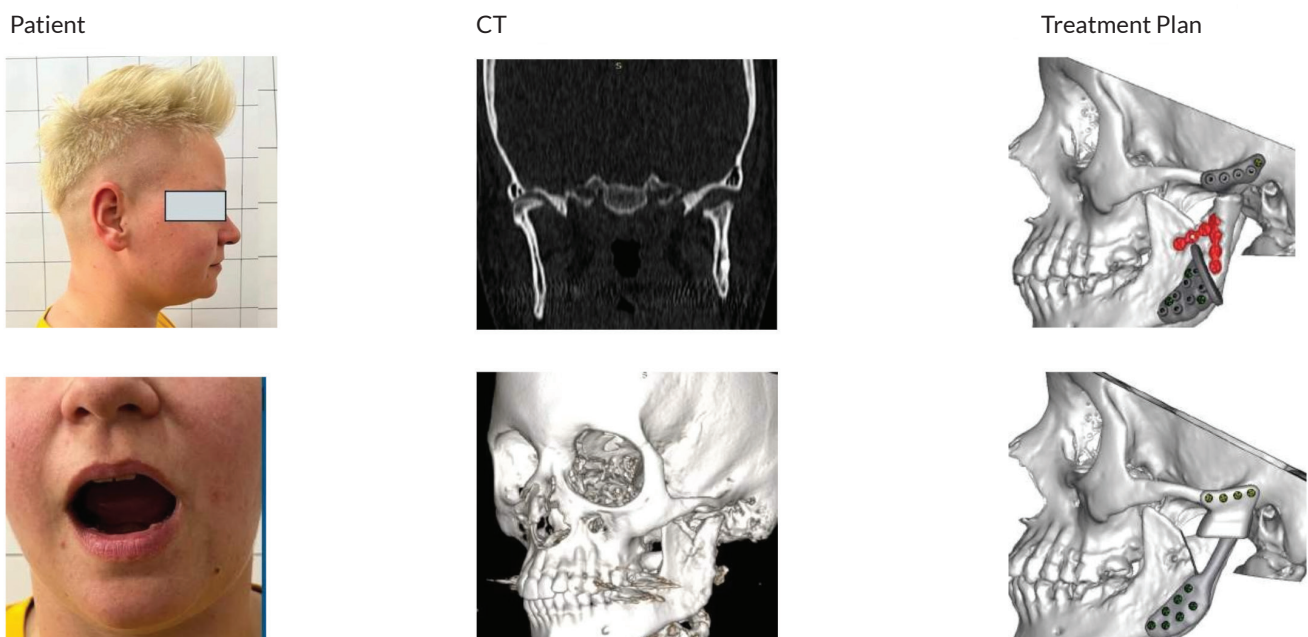


Figure 1. Case 1. Fracture of the condylar process of the mandible

tial compromise of masticatory function. Radiographic and cross-sectional imaging, including panoramic radiographs and CT scans, confirmed bilateral TMJ ankylosis with extensive joint surface destruction and remodeling. Given the severity of joint damage and the patient's functional impairment, a decision was made to proceed with bilateral TMJ replacement using custom-designed, patient-specific endoprostheses. The surgical plan was supported by a structured, multidisciplinary rehabilitation program focusing on postoperative physiotherapy, range-of-motion exercises, and long-term monitoring to prevent recurrence of ankylosis. The anticipated outcomes of the intervention included restoration of functional jaw movement, improved mastication and speech, partial correction of facial asymmetry, and enhancement of overall quality of life. Postoperatively, the patient exhibited substantial improvement: she achieved a maximal incisal opening of 30 mm, experienced marked reduction in pain, and reported significant gains in daily activities and psychosocial well-being, supported by an effective and sustained rehabilitation program.

Figure 2 shows the preoperative assessment and virtual surgical planning for TMJ prosthetic reconstruction. This figure presents the clinical, radiological, and digital planning workflow for TMJ replacement. In the left column (Patient), frontal and intraoral photographs show facial asymmetry and significant mandibular deviation with restricted opening, reflecting severe joint dysfunction. The middle column (CT) presents coronal CT and 3D volume renderings, which reveal extensive bony destruction and asymmetry of the mandibular condyles, confirming the need for joint replacement. The right column (Treatment plan) shows computer-assisted surgical planning, illustrating the design of a patient-specific TMJ prosthesis. The red-highlighted component marks the resected joint area, while the surrounding structures show custom fixation hardware tailored for anatomical precision and biomechanical stability (Fig. 2).

Case 3. Ameloblastoma of the mandibular body

A 67-year-old male presented with a long-standing history of progressive mandibular swelling, marked facial asymmetry, and intermittent purulent discharge from the oral cavity persisting for over a year. The patient reported pain, difficulty in mastication, and reduced oral intake. Physical examination revealed gross lower jaw deformity with notable displacement of the chin and malocclusion, as well as restricted mandibular movements, and intraoral fistulae with chronic mucosal infection. Contrast-enhanced CT imaging demonstrated an extensive, multilocular radiolucent lesion involving the mandibular body and bilateral rami, with significant cortical bone destruction and soft tissue extension. Histopathological analysis of the biopsy confirmed a solid/multicystic ameloblastoma, a benign but locally aggressive odontogenic tumor.

The management plan included wide surgical resection of the affected mandibular segments with tumor-free margins, followed by immediate reconstruction using a patient-specific TMJ endoprosthesis designed to restore mandibular contour and joint function. Postoperatively, the patient underwent a structured rehabilitation program encompassing physiotherapy for jaw mobilization, nutritional support, and regular clinical monitoring. The treatment goals were complete tumor eradication, restoration of mandibular continuity and function, and improvement of facial aesthetics. The outcome was highly favorable: the infection fully resolved, jaw opening and masticatory function improved substantially, and facial symmetry was effectively restored. These results were achieved through meticulous surgical technique and coordinated multidisciplinary rehabilitation.

Figure 3 shows the clinical presentation, imaging, and surgical planning for extensive mandibular reconstruction with TMJ prosthesis. This figure documents the case

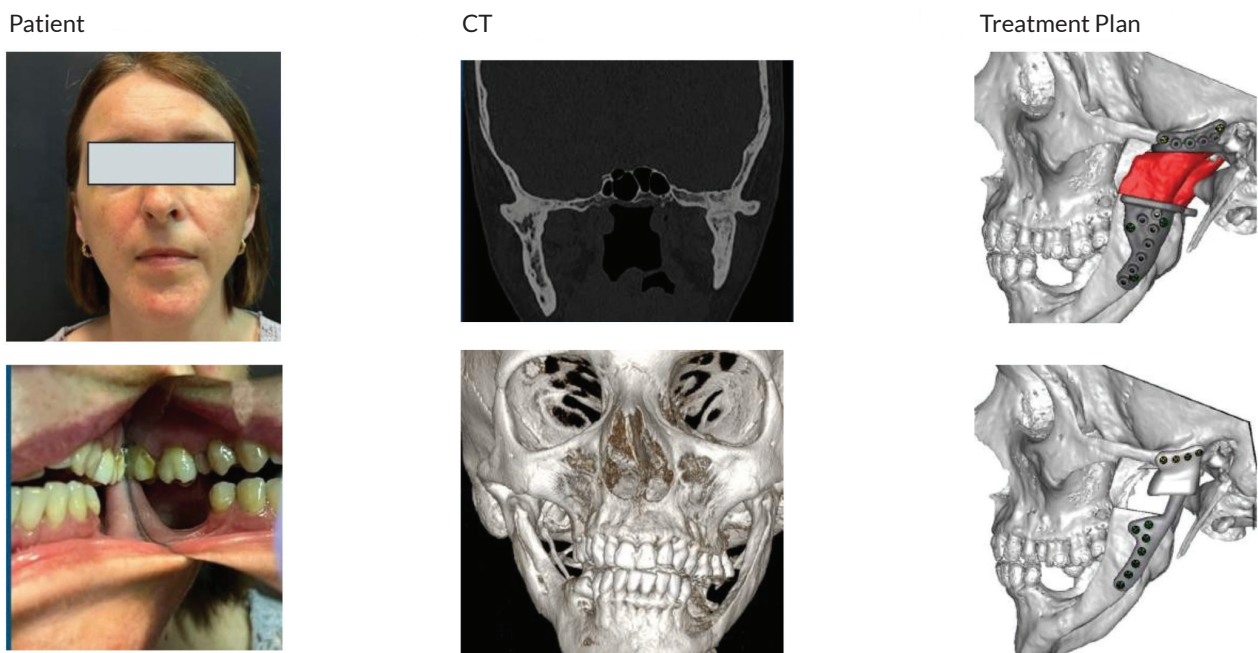

Figure 2. Case 2. Bilateral ankylosis of the temporomandibular joints

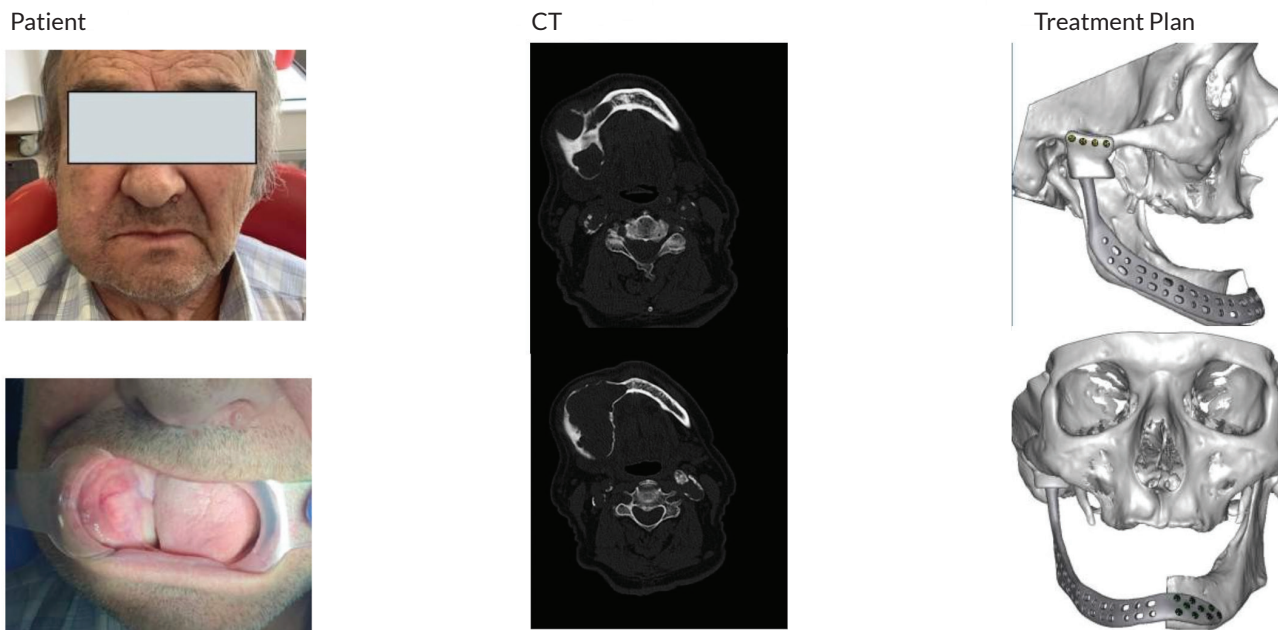


Figure 3. Case 3. Ameloblastoma of the mandibular body and rami, presenting with facial asymmetry and persistent intraoral purulent discharge for over one year

of a patient with severe mandibular pathology requiring full joint and mandibular body reconstruction using a custom alloplastic prosthesis. The left column (Patient) shows clinical images with facial asymmetry and intraoral evidence of significant mandibular loss, likely due to tumor resection or trauma, resulting in compromised occlusion and oral function. The middle column (CT) presents axial CT slices demonstrating extensive bony defects involving the mandibular ramus and body, highlighting the need for a large-scale reconstructive approach. The right column (Treatment plan) shows virtual surgical planning of a custom-designed mandibular prosthesis spanning from the TMJ region to the contralateral body, secured with fixation plates. The design accommodates complex anatomical deficits and aims to restore mandibular continuity, articulation, and symmetry.

Prehabilitation, surgical planning, and rehabilitation

Each patient undergoing temporomandibular joint (TMJ) replacement at the Department of Craniofacial and Maxillofacial Surgery in Katowice follows a comprehensive treatment pathway that includes detailed diagnostic imaging, individualized surgical planning, operative intervention, and both pre- and post-operative rehabilitation. Prior to surgery, thorough clinical and radiological evaluations, including CT scans, are performed to assist in designing custom-made TMJ endoprotheses tailored to patients' anatomical needs. This preparatory phase ensures a precise surgical approach and contributes to optimal outcomes.

Prehabilitation, the rehabilitation process initiated before surgery, is a critical component of care. It focuses on improving muscle function, educating the patient, and preparing soft tissues for the procedure. Following surgery, rehabilitation becomes central to restoring jaw mobility, speech, and facial symmetry. Postoperative therapy includes techniques aimed at reestablishing normal

sensory perception in the facial region and stimulating lymphatic drainage to minimize swelling and inflammation. At our department in Katowice, the rehabilitation program employs a range of modern physiotherapeutic modalities. These include Biopteron lamp therapy, which uses polarized light to stimulate healing; laser therapy, for its anti-inflammatory and regenerative effects; and the TheraBite® system, a jaw motion rehabilitation modality that assists in improving mandibular range of motion. Electrostimulation is used to activate and strengthen masticatory muscles, while kinesiotaping (used in step 02 of therapy) supports soft tissues and aids lymphatic drainage. This multimodal approach ensures holistic recovery, maximizing functional restoration and patient comfort.

Figure 4 shows the postoperative rehabilitation modalities following TMJ replacement surgery. This figure showcases three key components of the individualized rehabilitation protocols used to optimize recovery after TMJ replacement. In the top row (1), the left panel (Kinesiotaping) shows the application of kinesiotape to the lower face to support lymphatic drainage, reduce swelling, and aid in soft tissue healing. The center panel (Biopteron lamp) illustrates the use of Biopteron light therapy to promote cellular regeneration, reduce inflammation, and accelerate tissue repair. The right panel (TheraBite System) shows the use of the TheraBite device to increase mandibular range of motion through passive stretching. The middle row (2) includes close-up views of dental alignment and occlusion during functional recovery, assisted mouth opening, and jaw mobility measurements using the TheraBite scale. The bottom row (3) shows frontal and submental views of an elderly patient post-rehabilitation, demonstrating restored symmetry, improved range of motion, and enhanced mandibular contour.

The results of therapy following reconstruction surgery using diagnostic templates and previously excised

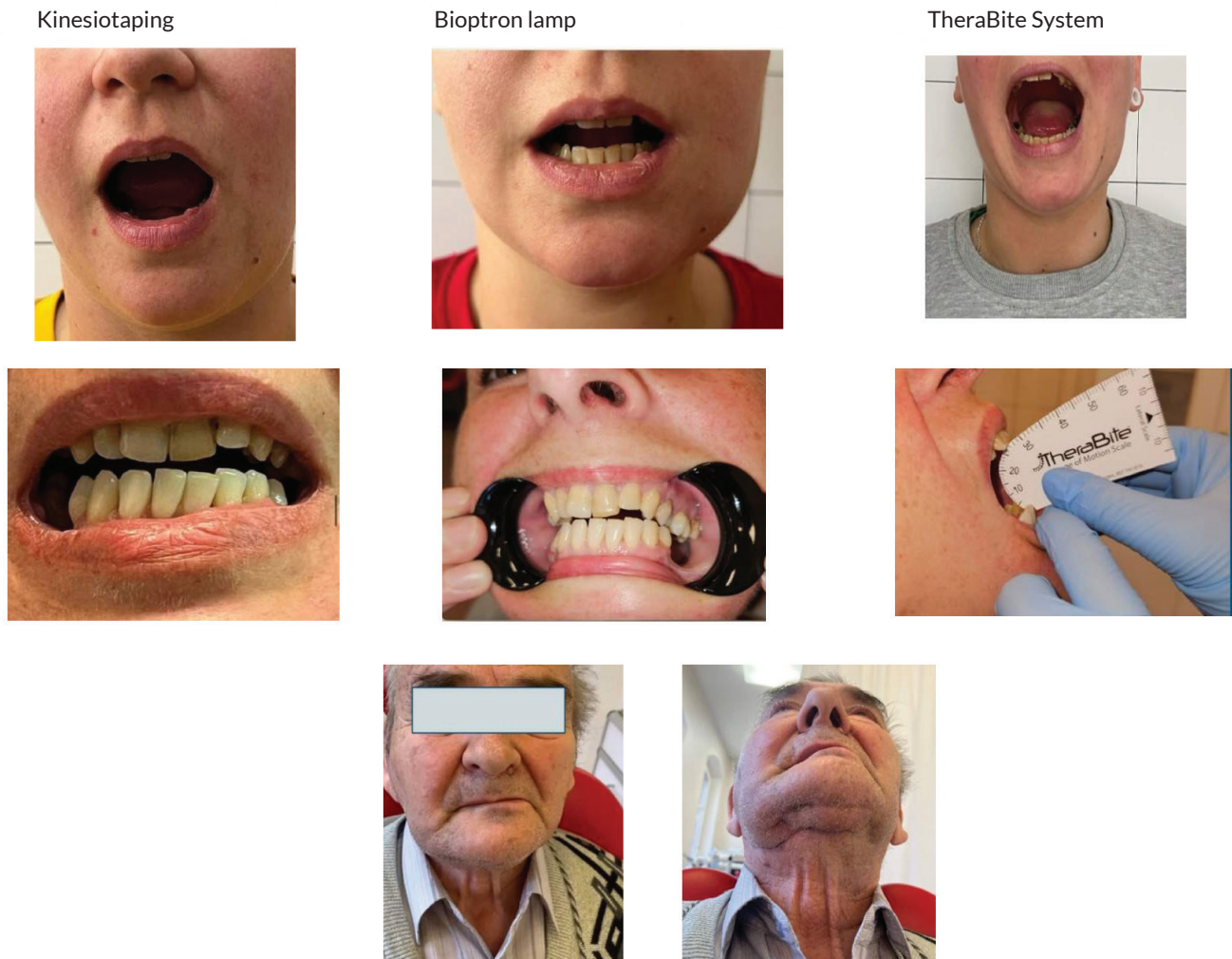


Figure 4. Postoperative outcomes following rehabilitative therapy

bone blocks were highly favorable. Patients experienced a marked return of normal stomatognathic system functions, including improved mandibular movement, clearer articulation, effective chewing, proper swallowing, and unimpeded respiration. In addition to restoring these vital functions, the rehabilitation process significantly enhanced overall comfort and quality of life. Pain was effectively abolished, postoperative swelling was eliminated, and patients reported a noticeable improvement in their general well-being.

Discussion

Temporomandibular joint (TMJ) disorders pose a unique challenge in maxillofacial surgery due to their multifactorial etiology, functional importance, and impact on a patients' quality of life [11, 12]. This case report highlights the critical role of not only surgical intervention but also extensive rehabilitation in restoring complete stomatognathic function and improving overall well-being. While TMJ replacement using custom-made endoprostheses is a highly advanced surgical option, it is the integration of individualized physiotherapy and prehabilitation that ultimately determines the long-term success of these procedures [13]. In this context, prehabilitation, comprising targeted physiotherapy, myofascial release, stretching exercises, neuromuscular coordination training, patient

education, and low-level laser therapy, played a pivotal role in optimizing muscular tone, improving joint mobility, reducing inflammation, and enhancing soft tissue resilience. By conditioning the stomatognathic system prior to surgery, this multimodal approach helped minimize perioperative complications, facilitated smoother surgical access, and laid the groundwork for more effective postoperative recovery [14, 15]. Structured application of these therapies, initiated weeks before surgery and tailored to each patient's specific limitations, allowed clinicians to establish baseline function and monitor improvements over time.

The three presented cases, ranging from trauma-induced fractures to extensive neoplasms and long-standing ankylosis, demonstrate the breadth of clinical scenarios in which TMJ reconstruction is indicated. Each case illustrates the importance of coordinated multidisciplinary care in overcoming severe anatomical and functional impairments. A review of current literature underscores the growing use of custom alloplastic TMJ replacements in patients with complex joint pathologies [16–20].

Yadav et al. reported that alloplastic total TMJ replacement is now considered a standard of care for adult patients with end-stage TMJ disease. They highlighted that advances in implant design, materials, and surgical tech-

niques have led to improved outcomes, including restoration of function and form, pain reduction, enhanced quality of life, and maintenance of ramal height. In cases of TMJ ankylosis, the procedure also decreases the risk of re-ankylosis and enables correction of facial asymmetry. However, the authors noted that current evidence is insufficient to support the use of this approach in skeletally immature patients [21].

Furthermore, research emphasizes the importance of functional rehabilitation in achieving maximum post-surgical benefit. Techniques such as laser therapy, electrostimulation, and mechanical jaw movement aids (e.g., the TheraBite system) have been validated in various clinical studies for their role in reducing inflammation, improving muscle tone, and expediting the return of normal mandibular function [22–25]. Despite these advances, gaps remain in the standardization of rehabilitation protocols, particularly in integrating modalities such as Biopton light therapy and kinesiotaping into post-TMJ replacement care [26]. This case series contributes to filling that gap by offering practical insight into how such techniques can be applied in routine clinical practice.

The presented cases align with the literature in supporting the view that rehabilitation is not merely a supportive add-on but rather an essential component of TMJ reconstruction [4]. In all three patients, outcomes such as restoration of articulation, mastication, swallowing, and respiration, as well as complete resolution of pain and swelling, were directly correlated with the intensity and duration of the rehabilitation process. Importantly, this report highlights the value of prehabilitation, a relatively underreported strategy that prepares soft tissues and neuromuscular pathways for surgical trauma, potentially reducing complications and accelerating recovery.

By outlining these comprehensive care pathways, this report not only reinforces current understanding but also expands best practices, advocating for the integration of individualized, multimodal rehabilitation as a clinical standard in TMJ joint replacement surgery.

In conclusion, this case report supports the growing consensus that successful outcomes in TMJ replacement depend as much on high-quality rehabilitation as on surgical precision. The evidence presented here both corroborates and extends existing knowledge regarding post-reconstructive care. It further emphasizes the need for interdisciplinary collaboration and protocol-driven rehabilitation strategies to optimize patient outcomes and redefine standards in oral and maxillofacial surgery.

Conclusion

Temporomandibular joint replacement is an effective surgical intervention for severe joint conditions, but its success depends equally on personalized, multimodal rehabilitation. This report highlights three cases in which custom-made endoprostheses, combined with therapies such as laser treatment, electrostimulation, and kinesiotaping, led to faster recovery and improved outcomes. These cases underscore the importance of interdisciplin-

ary care and structured rehabilitation as essential components of successful TMJ surgery.

Acknowledgements

The authors would like to thank Professor Iwona Niedzielska for providing the conceptual framework and sharing essential research material, and Doctor Daria Wziątek-Kuczmik for her assistance in manuscript preparation and approval of the final version.

References

1. Maini K, Dua A. Temporomandibular Syndrome. [Updated 2023 Jan 30]. In: StatPearls [Internet]. Treasure Island (FL): StatPearls Publishing; 2025 Jan-. Available from: <https://www.ncbi.nlm.nih.gov/books/NBK551612/>
2. Kapos FP, Exposto FG, Oyarzo JF, Durham J. Temporomandibular disorders: a review of current concepts in aetiology, diagnosis and management. *Oral Surg*, 2020; 13: 321–334. doi: 10.1111/ors.12473
3. Hoffmann RG, Kotchen JM, Kotchen TA, et al. Temporomandibular disorders and associated clinical comorbidities. *Clin J Pain*, 2011; 27: 268–274. doi: 10.1097/AJP.0b013e31820215f5
4. National Academies of Sciences, Engineering, and Medicine; Health and Medicine Division; Board on Health Care Services; Board on Health Sciences Policy; Committee on Temporomandibular Disorders (TMDs): From Research Discoveries to Clinical Treatment; Temporomandibular Disorders: Priorities for Research and Care. Yost O, Liverman CT, English R, Mackey S, Bond EC, editors. Washington (DC): National Academies Press (US); 2020 Mar 12. PMID: 32200600. Available from: <https://www.ncbi.nlm.nih.gov/books/NBK557986/>
5. Shackelford TK, Larsen RJ. Facial asymmetry as an indicator of psychological, emotional, and physiological distress. *J Pers Soc Psychol*, 1997; 72: 456–466
6. Vishwakarma A, Sharpe P, Shi S, Ramalingam M, eds. Stem cell biology and tissue engineering in dental sciences. 1st ed. Boston: Elsevier; 2014
7. Pruszyńska P, Kozakiewicz M, Szymor P, Wach T. Personalized temporomandibular joint total alloplastic replacement as a solution to help patients with non-osteosynthesizable comminuted mandibular head fractures. *J Clin Med*, 2024; 13: 5257. doi: 10.3390/jcm13175257
8. Wu Y, Liu J, Kang L, et al. An overview of 3D printed metal implants in orthopedic applications: Present and future perspectives. *Heliyon*, 2023; 9: e17718. doi: 10.1016/j.heliyon.2023.e17718
9. Guarda-Nardini L, Manfredini D, Berrone S, Ferronato G. Total temporomandibular joint prosthesis as a surgical option for severe mouth opening restriction. A case report of a bilateral intervention. *Reumatismo*, 2007; 59: 322–327. doi: 10.4081/reumatismo.2007.322
10. Lifková M, Czako L, Hirjak D, et al. Optimizing dental implant survival in microvascular jaw reconstruction: a comprehensive review of risk factors, clinical outcomes, and future directions. *Bratisl Med J*, 2025; 126: 600–608. doi: 10.1007/s44411-025-00076-x
11. Guidelines to writing a clinical case report. *Heart Views*, 2017; 18: 104–105. doi: 10.4103/1995-705X.217857

12. Warzocha J, Gadomska-Krasny J, Mrowiec J. Etiologic Factors of Temporomandibular Disorders: A Systematic Review of Literature Containing Diagnostic Criteria for Temporomandibular Disorders (DC/TMD) and Research Diagnostic Criteria for Temporomandibular Disorders (RDC/TMD) from 2018 to 2022. *Healthcare*, 2024; 12: 575. doi: 10.3390/healthcare12050575
13. Mani B, Balasubramaniam S, Balasubramanian S, et al. Role of custom-made prosthesis for temporomandibular joint replacement in unilateral ankylosis – an evaluative study. *Ann Maxillofac Surg* 2020; 10: 344–352. doi: 10.4103/ams.ams_132_20
14. Jeske P, Wojtera B, Banasiewicz T. Prehabilitation – current role in surgery. *Pol Przegl Chir*, 2022; 94: 64–72. doi: 10.5604/01.3001.0015.7340
15. Wilson CM, Ronan SL. Rehabilitation postfacial reanimation surgery after removal of acoustic neuroma: a case study. *J Neurol Phys Ther*, 2010; 34: 41–9. doi: 10.1097/NPT.0b013e3181cfc324
16. Liu H, Huang L, Liu S, et al. Evolution of temporomandibular joint reconstruction: from autologous tissue transplantation to alloplastic joint replacement. *Int J Oral Sci* 2025; 17: 17. <https://doi.org/10.1038/s41368-024-00339-3>
17. Mercuri LG. Alloplastic temporomandibular joint replacement: rationale for the use of custom devices. *Int J Oral Maxillofac Surg* 2012; 41: 1033–1040. doi: 10.1016/j.ijom.2012.05.032
18. Alali YS, Al Habeeb K, Al Malhook K, et al. Utilization of alloplastic prostheses in the extended reconstruction of the temporomandibular joint: a review of the literature. *J Clin Med*, 2024; 13: 6748. doi: 10.3390/jcm13226748
19. Khattak YR, Ghaffar N, Gulzar MA, et al. Can growing patients with end-stage TMJ pathology be successfully treated with alloplastic temporomandibular joint reconstruction? – A systematic review. *Oral Maxillofac Surg*, 2024; 28: 529–537. doi: 10.1007/s10006-023-01180-4
20. Correia Lima B, Grillo R, Alvarez Quinta Reis B, et al. Use of alloplastic total joint replacement of the temporomandibular joint of growing patients: a scoping review. *Eur J Ther*, 2024; 30: 531–536. doi: 10.58600/eurjther2152
21. Yadav P, Roychoudhury A, Kumar RD, et al. Total alloplastic temporomandibular joint replacement. *J Maxillofac Oral Surg*, 2021; 20: 515–526. doi: 10.1007/s12663-021-01628-8
22. Pinto-Borges H, Carvalho O, Henriques B, et al. A preliminary analysis of the wear pathways of sliding contacts on temporomandibular joint total joint replacement prostheses. *Metals*, 2021; 11: 685. doi: 10.3390/met11050685
23. Steen JP, Jaiswal KS, Kumbhare D. Myofascial pain syndrome: an update on clinical characteristics, etiopathogenesis, diagnosis, and treatment. *Muscle Nerve*, 2025; 71: 889–910. doi: 10.1002/mus.28377
24. Hamid S, Hayek R. Role of electrical stimulation for rehabilitation and regeneration after spinal cord injury: an overview. *Eur Spine J*, 2008; 17: 1256–1269. doi: 10.1007/s00586-008-0729-3
25. Rashiq S, Galer BS. Proximal myofascial dysfunction in complex regional pain syndrome: a retrospective prevalence study. *Clin J Pain*, 1999; 15: 151–153. doi: 10.1097/00002508-199906000-00013
26. Alowaimier HA, Al Shutwi SS, Alsaegh MK, et al. Comparative efficacy of non-invasive therapies in temporomandibular joint dysfunction: a systematic review. *Cureus*, 2024; 16: e56713. doi: 10.7759/cureus.56713